



DOI: 10.5137/1019-5149.JTN.20424-17.1

Received: 27.03.2017 / Accepted: 12.07.2017

Published Online: 19.09.2017

Case Report

Ruptured Distal Accessory Anterior Cerebral Artery Aneurysm: A Case Report and Literature Review

Alperen SIRIN, Ulas CIKLA, Kutluay ULUC, Mustafa K. BASKAYA

University of Wisconsin, Medical School, Department of Neurological Surgery, Madison, WI, USA

ABSTRACT

Aneurysms of the distal anterior cerebral artery (dACA) are rare, consisting only 2-6% of all intracranial aneurysms. dACA aneurysms are often associated with anomalies such as azygous, bihemispheric and triplication of ACA. Also, accessory anterior cerebral artery (accACA) is an anatomical variant found in 3.3% to 15% of the population. Here we report a case of a 60-year-old female who presented with a Hunt and Hess grade II, Fisher grade III subarachnoid hemorrhage secondary to a ruptured saccular aneurysm originating from the pericallosal-callosomarginal artery bifurcation at the A3 segment of the accACA and underwent an uncomplicated microsurgical clipping.

KEYWORDS: Accessory anterior cerebral artery, Ruptured aneurysm, Third A2

ABBREVIATIONS: ACA: Anterior cerebral artery, dACA: Distal anterior cerebral artery, accACA: Accessory anterior cerebral artery, MACC: Median artery of corpus callosum, CC: Corpus callosum, SAH: Subarachnoid hemorrhage

INTRODUCTION

Distal anterior cerebral artery (dACA) aneurysms are rare; Yasargil reported only a 2.3% incidence in a review of 1400 aneurysms (15). A large review of aneurysms from 2 Finnish neurosurgical centers found dACA aneurysms consists 6% of all intracranial aneurysms (5). In general, dACA aneurysms are often associated with anomalies such as azygous, bihemispheric and triplication of ACA (1,5,16). Lehecka et al. reviewed 101 cases of dACA aneurysms and found abnormalities of ACA in 23 patients: azygous ACA in 4 patients (4%), bihemispheric ACA in 15 patients (15%), and triplication of ACA in 4 patients (4%)(5).

Among these anomalies, a triplicated ACA is one of these featured variations and, frequently referred as a median artery of the corpus callosum (MACC). MACC supplies branches to the corpus callosum (CC), adjacent cortex, septal nuclei, septum pellucidum and upper portion of the column of the

fornix. If this MACC supplies one or more of the usual cortical branches of ACA, Baptista classified this anatomical variant as accessory ACA (accACA) (Figure 1) (1). The accACA is an anatomical variation reported to occur in 3.3 to 15% of individuals (1,2,6,11,12). Furthermore, the aneurysms of this anatomical variant are less common, and few case reports were reported in the literature. Most of the distal accACA aneurysm cases in the literature are at the A4 and A5 segments and distal accACA aneurysms are parallel to dACA aneurysms regarding tendency to rupture, small size and good outcome after direct surgery (4,5,7-10,14).

We, therefore, present our case of a distal accACA aneurysm at A3 segment and literature review in this report.

CASE REPORT

A 60-year-old woman presented with sudden onset severe headaches and nausea. She was a non-smoker with a



Corresponding author: Mustafa K. BASKAYA

E-mail: baskaya@neurosurgery.wisc.edu

medical history of hyperlipidemia, obstructive sleep apnea, and asthma. Her sister had five intracranial aneurysms and had experienced subarachnoid hemorrhage (SAH) as well.

On presentation, she was alert and fully oriented, with no motor or cranial nerve deficits. An emergent head computed tomography (CT) revealed Fisher grade III SAH. CT-angiogram showed a 4 x 5 mm A3 segment aneurysm of accACA. On the four-vessel diagnostic angiogram, bilateral A1 segments were of average size and the AcomA was oriented in the

anteroposterior axis rather than mediolateral. Three ACA A2 segments coursing over the CC were seen (Figures 2, 3). The aneurysm was located at the bifurcation of the accACA. She was taken to the operating room for microsurgical clipping, and she tolerated the surgery well without any complications. She was discharged 14 days after the initial bleed. A postop-

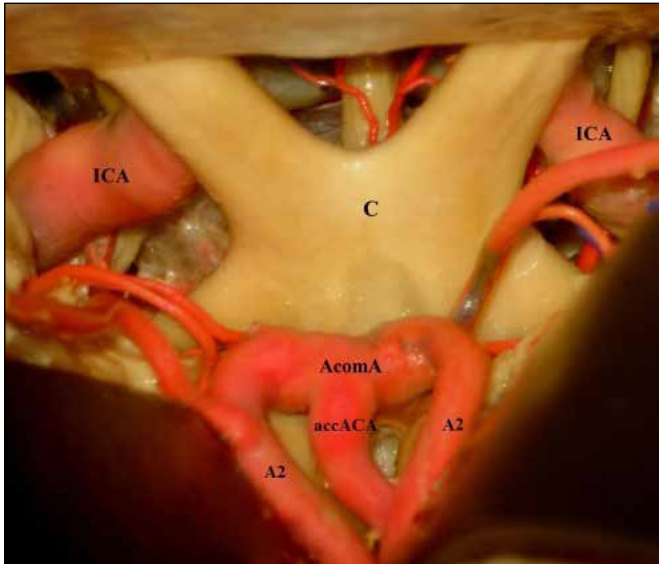


Figure 1: Anatomical dissection of a perfused cadaveric head shows a third A2 variant artery branching from the AcomA.

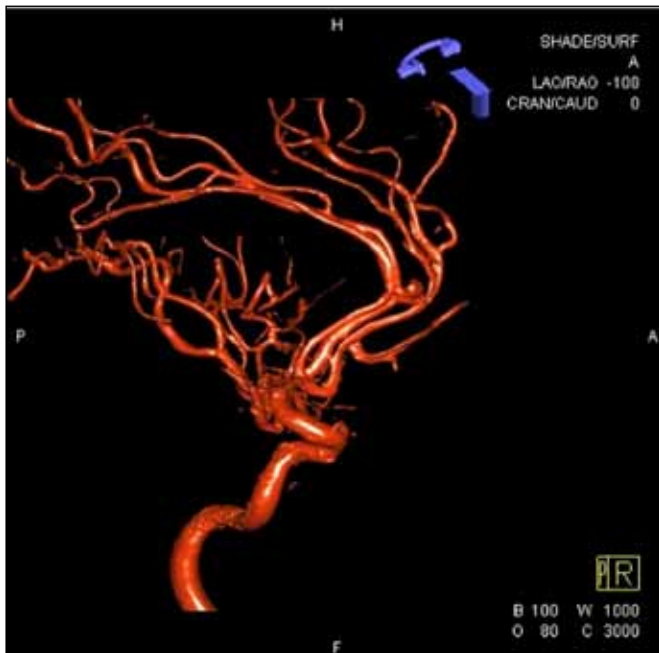


Figure 3: 3D reconstruction of diagnostic angiogram reveals the aneurysm close to the bifurcation of the pericallosal and callosomarginal arteries and all three A2 branches.

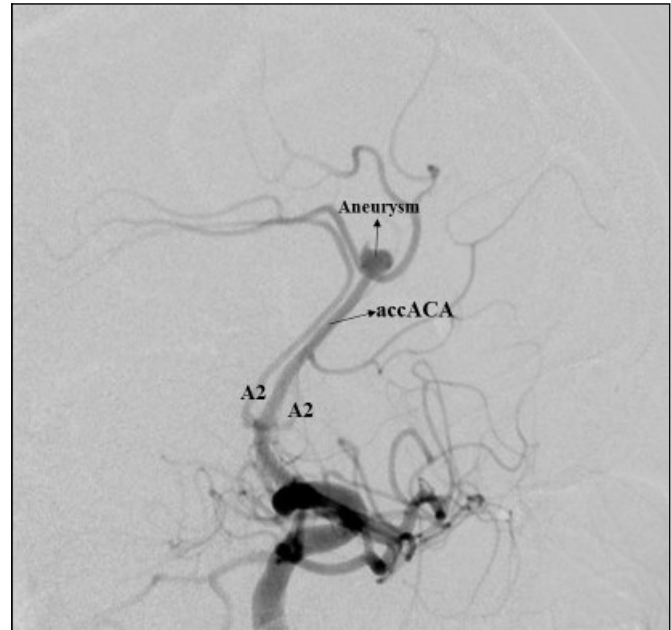


Figure 2: Diagnostic angiogram reveals the presence of three A2 segments running over the CC, with an aneurysm formed on the middle segment, or accACA.

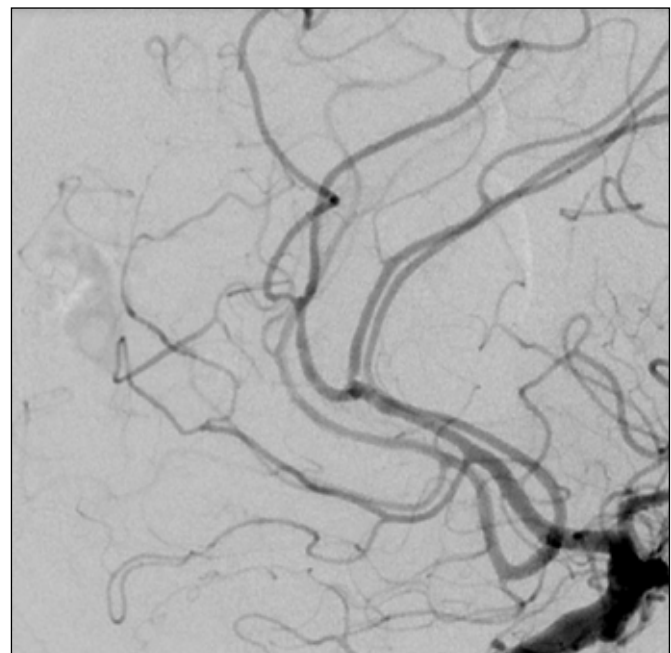


Figure 4: Postoperative angiogram shows complete occlusion of the aneurysm, with preservation of the blood flow through all branches.

erative angiogram confirmed the complete occlusion of the aneurysm with preservation of the parent vessels (Figure 4).

■ DISCUSSION

The anatomy of the ACA is highly variable (1,15). The most common variations of ACA are azygos ACA, bihemispheric ACA, triplication of ACA, and crossover of branches to the contralateral hemisphere (1). Baptista examined 381 brains and found azygos ACA in 1 case (0.26%) and bihemispheric ACA in 45 cases (12%)(1). In 20 brains (5%) a right ACA sent a branch to the left hemisphere and in 25 brains (7%) a left ACA sent a branch to the right hemisphere (1). The triplication of ACA is a previously described, well-known variation. Baptista found accACA in 50 brains (13%)(1). Yasargil found triplication of the ACA in 9% of the cadaver dissections and 9.6% of the operative cases (16).

The nomenclature of this anatomical variation is often unclear and confusing. Several names have been used for this variation: medial ACA, the median callosal artery, the superior callosal artery, third A2 artery and accACA (1,16). Baptista's description of this variation attempted to clarify nomenclature. Baptista favored the term "median artery of CC" when this artery gives branches to the CC, adjacent cortex, septal nuclei, septum pellucidum and the upper portion of the column of the fornix. If this artery gives branches to the cortical surface, it was classified as accACA (1). If this artery does not even reach to CC, he recommended using the term "subcallosal artery" (1). In our case, this artery supplies the cortex. There, we classified this artery as accACA. The incidence of the accACA has been reported between 3.3% and 15% (1,2,6,11,12).

The incidence of aneurysms in distal accACA is even less common. There are only 12 cases including ours that have been previously reported in the literature (4,5,7-10,14).

In the literature, all reports as well as ours consisted of cases with an aneurysm on bifurcation or trifurcation on distal accACA (Table I). Matsuzaki et al. proposed an explanation for this phenomenon by suggesting that hemodynamic stress on the bifurcation and trifurcation often led to the formation of an aneurysm (7). Seven of the previously reported accACA aneurysms were in the A5 segment, Lehecka et al. reported 4 aneurysms at the distal part of triplicated branch of ACA, which 2 of them were in the A3 segment and 2 of them were in the A4 segment (4,5,7-10,14). Although the occurrence of distal accACA aneurysms in the A3 segment is rare, 78.2-85.7% of the dACA aneurysms occur at the A3 segment (3,5). The occurrence of dACA aneurysms in A4 and A5 segments is exceptionally rare, and only occur in 6-7.6% of dACA aneurysms (3,5,13). In contrast, 9 of previously reported 11 distal accACA aneurysm cases were in the A4 and A5 segments and this incidence can be explained by the previously mentioned hemodynamic stress at the bifurcation or trifurcation phenomenon (4,5,7-10,14). In our case, the aneurysm was at the A3 branch as seen in 2 of the previously reported 11 distal accACA aneurysm cases (5).

Treatment options for the dACA aneurysms are surgical clipping or endovascular coiling. However, due to their small size, relatively wide neck, and a small caliber of the parent artery, endovascular coiling of dACA aneurysms is reportedly more challenging compared to the other aneurysms (7). In all distal accACA aneurysm cases, clipping was the favored

Table I: Reports of Cases with an Aneurysm on Bifurcation or Trifurcation on Distal accACA

Author (year)	Age (years)/ Sex	Presentation	Rupture	Type of accessory ACA	Segment	Treatment	Outcome
Shimosegawa et al. (1985)	66/F	Loss of consciousness and severe headache	ruptured	Bihem.	A5, bifurcation	clipping	excellent
Morioka et al. (1997)	63/M	Severe headache then loss of consciousness and paraplegia	ruptured	Bihem.	A5, bifurcation	clipping	excellent
Mitsuyama et al. (2001)	59/M	Sudden headache	ruptured	Bihem.	A5, bifurcation	clipping	excellent
Kutsuna et al. (2006)	66/F	Chronic headache	unruptured	Bihem.	A5, trifurcation	clipping	excellent
Morigaki et al. (2008)	67/F 72/F	Chronic headache Sudden vomiting and loss of consciousness	unruptured ruptured	Bihem. Bihem.	A5, bifurcation A5, trifurcation	clipping coiling then clipping	excellent good
Matsuzaki et al. (2011)	48/M	Sudden onset of headache	ruptured	Bihem.	A5, bifurcation	clipping	excellent
Present Case	60/F	Sudden headache and nausea	ruptured	Bihem.	A3, bifurcation	clipping	excellent

Bihem: Bi-hemispheric, **M:** Male, **F:** Female, **ACA:** Anterior cerebral artery.

treatment modality and the outcomes were excellent in all but one, a 72-year-old female who had coiling followed by clipping of the aneurysm.

■ CONCLUSION

A complete understanding of anatomical variations of the cerebral vasculature is crucial for the treatment of complex vascular lesions and in particular intracranial aneurysms. Identifying and understanding the anatomical variations would allow neurosurgeons to develop a more efficient plan of care.

■ REFERENCES

1. Baptista AG: Studies on the arteries of the brain. II. The anterior cerebral artery: Some anatomic features and their clinical implications. *Neurology* 13: 825-835, 1963
2. Gomes FB, Dujovny M, Umansky F, Berman SK, Diaz FG, Ausman JI, Mirchandani HG, Ray WJ: Microanatomy of the anterior cerebral artery. *Surg Neurol* 26:129-141, 1986
3. Hernesniemi J, Tapaninaho A, Vapalahti M, Niskanen M, Kari A, Luukkonen M: Saccular aneurysms of the distal anterior cerebral artery and its branches. *Neurosurgery* 31:994-999, 1992
4. Kutsuna M, Monden S, Watanabe K: Two cases of distal anterior cerebral artery aneurysm associated with accessory anterior cerebral artery. *No Shinkei Geka* 34:193-200, 2006 (In Japanese)
5. Lehecka M, Lehto H, Niemelä M, Juvela S, Dashti R, Koivisto T, Ronkainen A, Rinne J, Jääskeläinen JE, Hernesniemi JA: Distal anterior cerebral artery aneurysms: Treatment and outcome analysis of 501 patients. *Neurosurgery* 62:590-601, 2008
6. Marinkovic S, Milisavljevic M, Marinkovic Z: Branches of the anterior communicating artery. *Microsurgical anatomy. Acta Neurochir (Wien)* 106:78-85, 1990
7. Matsuzaki K, Uno M, Fujihara T, Miyamoto T, Yokosuka K, Toi H, Matsubara S, Hirano K: Ruptured distal accessory anterior cerebral artery aneurysm-case report. *Neurol Med Chir (Tokyo)* 51:839-842, 2011
8. Mitsuyama T, Shimuzu T, Kadowaki H: A ruptured accessory anterior cerebral artery aneurysm. *No Shinkei Geka* 10:461-464, 2001 (In Japanese)
9. Morigaki R, Uno M, Matsubara S, Satoh K, Nagahiro S: Choreoathetosis due to rupture of a distal accessory anterior cerebral artery aneurysm. *Cerebrovasc Dis* 25:285-287, 2008
10. Morioka M, Fujioka S, Itoyama Y, Ushio Y: Ruptured distal accessory anterior cerebral artery aneurysm: Case report. *Neurosurgery* 40:399-401, 1997
11. Nathal E, Yasui N, Sampei T, Suzuki A: Intraoperative anatomical studies in patients with aneurysms of the anterior communicating artery complex. *J Neurosurg* 76:629-634, 1992
12. Ogawa A, Suzuki M, Sakurai Y, Yoshimoto T: Vascular anomalies associated with aneurysms of the anterior communicating artery: Microsurgical observations. *J Neurosurg* 72:706-709, 1990
13. Ohno K, Monma S, Suzuki R, Masaoka H, Matsushima Y, Hirakawa K: Saccular aneurysms of the distal anterior cerebral artery. *Neurosurgery* 27:907-913, 1990
14. Shimosegawa Y, Takahashi A, Onuma T: Ruptured cerebral aneurysm of the median artery of the corpus callosum (accessory anterior cerebral artery): Case report. *No Shinkei Geka* 13:579-583, 1985 (In Japanese)
15. Yasargil MG: Distal anterior cerebral artery aneurysms. In: Yasargil MG (ed). *Microneurosurgery*. Vol II: Stuttgart: Georg Thieme Verlag, 1984: 224-231
16. Yasargil MG: Intracranial arteries: Distal anterior cerebral artery. In: Yasargil MG (ed). *Microneurosurgery*. Vol I: New York: Thieme Medical Publishers Inc, 1987: 116-128