



DOI: 10.5137/1019-5149.JTN.18009-16.2

Received: 24.04.2016 / Accepted: 01.07.2016

Published Online: 22.08.2016

Original Investigation

# Predictive Factors of the Management of Spinal Cord Arteriovenous Fistulas

Ahmed SULTAN<sup>1</sup>, Tamer HASSAN<sup>1</sup>, Waseem AZIZ<sup>1</sup>, Tamer IBRAHIM<sup>1</sup>, Ahmed YEHAIA<sup>1</sup>, Osama MANSOUR<sup>2</sup>

<sup>1</sup>Alexandria University, Department of Neurosurgery, Alexandria, Egypt

<sup>2</sup>Alexandria University, Department of Neurology, Alexandria, Egypt

## ABSTRACT

**AIM:** Spinal cord arteriovenous fistulas are rare cause of progressive myelopathy. The predictive factors of their outcome after endovascular or surgical treatment are still controversial.

**MATERIAL and METHODS:** Twenty patients were diagnosed with spinal arteriovenous fistulas; 13 of them had dural and 7 had perimedullary fistulas (1 Dorsal and 6 Ventral). Surgery, endovascular or both treatments were used.

**RESULTS:** Ten of the 13 patients in the dural group were surgically treated, while 2 were managed by embolization and one combined. Seven patients improved, while 6 patients showed stationary clinical course after intervention. Five patients in the perimedullary group were embolized with clinical improvement, 1 patient refused intervention, and 1 patient had surgery. Clinical improvement was significantly correlated to the duration of symptoms before intervention ( $p=0.012$ ), and preoperative neurological condition ( $p=0.001$ ). No significant correlation was found with age, anatomic level of the fistula, fistula type, and type of intervention.

**CONCLUSION:** Microsurgery was preferred for dural and dorsally located perimedullary fistula, while embolization was preferred for ventrally located ones. Clinical improvement was significantly correlated with early intervention and preoperative neurological condition of the patient. Age of the patient, fistula type, fistula location, and type of intervention did not show significant relation to the outcome. Patients could benefit from intervention even if they present with poor neurological condition.

**KEYWORDS:** Spinal arteriovenous fistula, Perimedullary, Predictive factor, Embolization

**ABBREVIATIONS:** **ALS:** Aminoff-Louge score, **AVF(s):** Arteriovenous fistula(s), **DAVF(s):** Dural arteriovenous fistula(s), **PMAVF(s):** Perimedullary arteriovenous fistula(s), **EVE:** Endovascular embolization, **NBCA:** N-butyl CyanoAcrylate, **MRI:** Magnetic resonance imaging, **CSF:** Cerebrospinal fluid

## INTRODUCTION

Direct connections between arteries and veins in the spinal canal result in different forms of spinal arteriovenous fistulas (AVFs). The most common form is the dural AVFs representing 80% of all cases (17,19,24,25). Other less common types include epidural and perimedullary fistulas.

Progressive motor weakness, sensory deficits, sphincteric disturbances and back pain are the most common clinical manifestations of such pathology. Some patients presented acutely due to hemorrhage or due to the Foix-Alajouanine syndrome (24,27,32,33,36). Hemorrhage, venous hypertension, arterial steal, ischemia, and consequently necrotizing myelopathy are the underlying pathophysiological mechanisms responsible for the clinical presentation (9,13,14,27).



Corresponding author: Tamer HASSAN

E-mail: neurocatheter@yahoo.com

Treatment modalities for spinal fistulas include: surgery and endovascular obliteration. Surgery for spinal dural arteriovenous fistulas (SDAVF), carries a low morbidity and low recurrence rates. An increasing number of patients are now being treated by minimally invasive endovascular embolization (17,20,25,27,30,37). Surgery for spinal perimedullary arteriovenous fistulas (PMAVFs) carries a higher morbidity than that for dural AVF while endovascular treatment carries a less morbidity (8,11,37).

We retrospectively evaluated our patients presenting with spinal AVFs after endovascular embolization (EVE) and/or surgical treatment and assessed predictive factors affecting the clinical outcome.

## ■ MATERIAL and METHODS

Twenty patients were diagnosed with spinal AVFs (dural or perimedullary) between 2006 and 2014 at Alexandria main university hospital. All patients were managed by either surgical or endovascular embolization after obtaining informed consent.

### Lesion Subtypes and Demographics

The total cohort included 20 patients; 13 of them had dural AVFs and 7 had perimedullary AVFs (Table I).

#### Patients with DAVFs

Twelve patients were male, with age ranging from 50 to 71 years (median: 56 years). All patients presented with progressive spastic paraparesis. Seven patients had sphincter disturbances.

#### Patients with PMAVFs

Patients in this group were 4 males and 3 females, with relatively younger age range (4 to 52 years; median 24 years). Five of the patients had Type B perimedullary fistula, 1 had type A and 1 had type C. The clinical presentation of patients in this group included two with acute paraplegia due to hemorrhage, 4 with progressive spastic paraparesis, and one with back pain only. Four patients suffered from sphincter disturbances.

#### Clinical Evaluation

All patients were evaluated using the Aminoff-Logue score (2) at the time of hospitalization and at follow-up (Table II).

#### Diagnostic Workup

Patients were evaluated by spinal magnetic resonance imaging (MRI) with and without contrast after clinical assessment. Typical features of spinal fistulas were present in all cases as signal voids, cord hyperintensity on T2 images, and cord enhancement with gadolinium. Upon recognition of these features on MRI, patients underwent spinal angiography.

#### Spinal Angiography

Spinal angiography was performed under either local or general anesthesia or under sedation according to the expected duration of the procedure. A 5 or 6 French femoral sheath and a 5 or 4 French diagnostic catheter were used. Complete

spinal angiogram was done for all the cases, starting from the internal iliac arteries, going up and examining the right and left radicular arteries, and both vertebral and both thyrocervical trunks.

### Anatomical distribution of cases (according to the origin of the feeders)

**Patients with DAVFs** (13 patients): Eight were dorsal in location and 5 cases were lumbar, supplied by radicular arteries from the aorta and internal iliac arteries (Table I).

**Patients with PMAVFs** (7 patients): One was right posterior at the D10 level, 6 had ventral fistulas (2 lower dorsal, 1 at D3, 1 cervicodorsal, and 2 at the conus medullaris) (Table I)

#### Follow-up

All patients were followed clinically and radiologically. The duration of follow-up ranged from 6 months to 5 years. In cases when the patient was not able to show up for examination, a telephone interview was conducted and it involved questioning the patient about his motor power, sensory changes, sphincter control, and ability to conduct his/her daily activities. Patient's answers were compared with his/her last follow-up and accordingly, a chart of patient progression was postulated.

#### Management Options

**Surgery:** Surgery was reserved for dorsally located fistulas (DAVF or perimedullary fistulas arising from the posterior spinal artery). It was performed via a posterior midline approach, with laminectomy or laminoplasty opposite the affected level and one level above and one level below. Opening of the dura was done at the midline. In cases of SDAVF, following the identification of the feeding artery and the draining vein in the dura of the posterior nerve root, intra-operative Doppler was used for confirmation, and then the arterialized draining vein was cauterized by bipolar forceps and cut to disconnect the fistula. Change in the color and turgor of the dilated spinal veins was usually observed immediately indicating disconnection of the fistula. In cases of posterior PMAVF, the fistula was found on the surface of the spinal cord, and it was carefully disconnected being careful not to jeopardize the posterior spinal artery.

**Endovascular embolization:** Embolization was performed through trans-femoral access. A guiding catheter was advanced into the desired segmental artery (Adamkiewicz in perimedullary fistulas), and then a microcatheter was advanced over a micro-guide wire until it reached the exact fistulous point and embolization was then performed. Initially, N-butyl Cyano Acrylate (NBCA) was used to embolize the fistula. Onyx was used in the later part of the series. In cases of SDAVF, the embolic material had to infiltrate until it reached the draining vein to ensure total occlusion. In cases of perimedullary AVF, we were careful not to occlude the spinal arteries with reflux of embolic material.

#### Clinical Outcome

Clinical outcome was evaluated based on the Aminoff-Logue score (ALS)(2). It is shown in Table II for each patient prior and

Table 1: All Cases Included in the Series

No	Age (years)	Sex	Presentation	Diagnosis	Treatment	Time to surgery	Pre-op ALS	Post-op ALS	Motor	Outcome	SO
1	61	M	Paraplegia, sphincter disturbances	Lt DAVF at D9	Surgery	1 year	5	5	G0 --- G1	P	NI
2	71	M	Progressive spastic paraparesis, sphincter disturbances	Rt DAVF at D12	EVE with glue	1 year	4	4	G3 --- G3	MD	NI
3	50	M	Progressive spastic paraparesis	Lt DAVF at D10	EVE (another institute) → surgery for recanalization via Rt D11 →	6 m	3	0	G4 --- G5	G	I
4	54	M	Progressive spastic paraparesis, sphincter disturbances	Rt DAVF at D11	Surgery	8 m	5	4	G2 --- G3	MD	NI
5	67	M	Progressive spastic paraparesis, sphincter disturbances	Rt DAVF at L5 (origination from Rt lateral sacral artery)	Surgery	9 m	4	4	G3 --- G3	MD	NI, Died SDH
6	54	M	Progressive spastic paraparesis	Lt DAVF at D9	Surgery	5 m	3	3	G4 --- G4	G	NI
7	50	M	G4 paraparesis, hemorrhage	Rt DAVF at D11	Surgery	1 m	3	0	G4 --- G5	G	I
8	50	M	Spastic Paraplegia, sphincter disturbances	Lt DAVF at D9	EVE with Onyx → Recanalization from Lt D10 RE embolized	1.5 y	5	5	G0 --- G0	P	NI
9	60	F	Cauda equina syndrome	Rt DAVF at L5 (origination from Rt lateral sacral artery)	Surgery	3M	5	0	G2 --- G5	G	I
10	53	M	Progressive spastic paraparesis	Rt DAVF at L1	Surgery	3 m	3	0	G4---G5	G	I
11	53	M	Progressive spastic paraparesis, Sphincter disturbances	Rt DAVF at L1	Surgery	2 m	5	4	G2---G3	MD	NI
12	50	M	Progressive spastic paraparesis	Lt DAVF at L1	Surgery	4 m	3	3	G4---G4	G	NI
13	35	M	Progressive spastic paraparesis	Lt DAVF at D 6	Surgery	2 m	4	0	G4-G5	G	I

Table 1: Cont.

No	Age (years)	Sex	Presentation	Diagnosis	Treatment	Time to surgery	Pre-op ALS	Post-op ALS	Motor	Outcome	SO
14	10	M	Paraplegia, hemorrhage, sphincter disturbances	Ventral PMAVF type B at the conus medullaris with ruptured aneurysmal varix	EVE with coils into the varix and glue injection	1 m	5	3	G0 --- G4	G	I
15	4	M	Tetraparesis, (missed as cerebral palsy)	Ventral cervico-dorsal perimedullary fistula type B	EVE with glue	9 m	5	0	G2 --- G5	G	I
16	30	F	Progressive spastic paraparesis, sphincter disturbances	Ventral PMAVF type C at D12 level	EVE with glue	15 ds	4	0	G3 --- G5	G	I
17	52	F	Progressive spastic paraparesis	Rt Dorsal PMAVF type A at D10 level	2 surgeries for the fistula and 3 <sup>rd</sup> surgery for acquired arachnoid cyst	3 m	4	3	G4 --- G4	G	NI
18	25	F	Back pain only	Ventral PMAVF type B, thoracolumbar.	Refusing surgery, on follow-up		0	0	intact	---	---
19	23	M	Progressive spastic paraparesis, Sphincter disturbances	Ventral PMAVF type B at the conus with 2 feeders from anterior spinal artery	EVE with Glue	10 days	5	0	G2 --- G5	G	I
20	8	M	Progressive spastic paraparesis, Sphincter disturbances	Ventral PMAVF type B at D3, Spinal cord hematoma	Surgery with hematoma evacuation then EVE with Glue after 3 m	1 m	5	3	G0 -G4	G	I

**ALS:** Aminoff-Louge score, **G:** good, **G:** motor power grade, **I:** improved, **m:** month, **MD:** moderate, **MO:** Motor outcome, **NI:** not improved, **O:** outcome, **P:** poor, **PI:** partial improvement, **SO:** Sphincter outcome, **M:** Male, **F:** Female, **Lt:** Left, **Rt:** Right, **SDH:** Subdural hematoma.

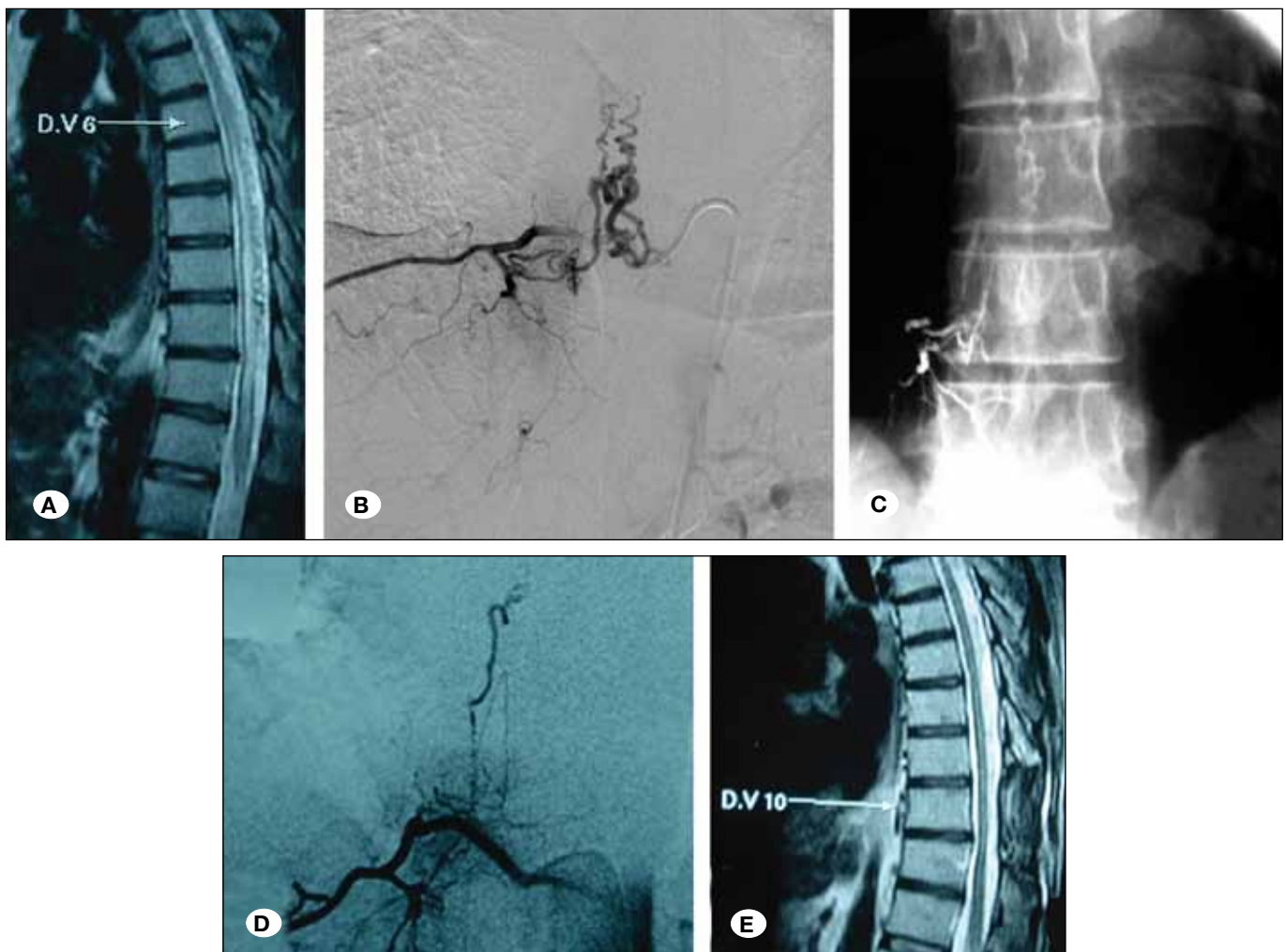
post treatment. A good outcome was considered as motor power of grade 4 or 5, meaning that the patient is able to walk and carry on his daily activities (ALS 1-2); moderate outcome was considered as motor power of 3, meaning that the patient would need crutches to walk (ALS 4); and poor outcome was considered as motor power of less than 3 (ALS 5).

#### Statistical Analysis of the Data

Data were analyzed using IBM SPSS software package version 20.0. Comparison between different groups regarding categorical variables was tested using the Chi-square test. When more than 20% of the cells have an expected count less than 5, correction for chi-square was conducted using Fisher's Exact test or the Monte Carlo correction.

**Table II:** Aminoff-Logue Motor Disability Scale (2)

Disability	Degree
Hypesthesia without gait restriction	1
Reduced tolerance to exercise	2
Need a cane for walking	3
Need for two canes or crutches to walk	4
Inability to stand: patient in wheelchair or in bed	5



**Figure 1:** (Patient 3) 50-year-old male patient who suffered from spastic paraparesis of grade 4 over the course of 6 months (ALS 3), he had an MRI (A) which showed spinal cord hyperintensity, edema and swelling along with signal voids on the dorsal aspect of the cord. He was diagnosed with spinal dural AVF at left D10 level on the basis of a spinal angiography which was done at another institute (B), a treatment attempt by embolization with Onyx was performed as well, but the Onyx could not hit the draining vein. X-ray showing the Onyx cast residing in the segmental artery and not reaching the vein (C). The patient did not show clinical improvement and was referred to our institute. Another spinal angiogram was done which showed recanalization of the fistula from the lower feeder at right D11 segmental artery (D). Surgery was done, and clinical follow-up showed complete recovery of the symptoms (ALS 0). Follow-up MRI showed resolution of the spinal cord hyperintensity and signal voids (E).

## RESULTS

### Patients with DAVFs (Figure 1A-E)

Eleven patients in this group were managed successfully by surgical disconnection of the dural fistula via a posterior approach (one of them (patient 3) had surgery after failed EVE at another institute). Complete fistulous occlusion was obtained with surgery. Two patients were managed by EVE, one with NBCA (patient 2) and one with Onyx (patient 8). Patient 8 had was in poor medical condition that prohibited surgery; follow-up showed recanalization of the fistula after the first session and another session of EVE was done (Table I).

### Patients with PMAVFs

Six patients were diagnosed with ventral PMAVFs and one patient had a dorsal one (Figures 2A-F, 3H-I). Five patients in this group suffering from ventral fistulas were managed by EVE with liquid agents and one with coils and glue (Patient 14). One patient (patient 17) who had a dorsal perimedullary fistula type A was managed by surgical disconnection via a posterior approach but he had complications that are described thoroughly later in the text and Patient 18 refused intervention because he only had back pain and did not accept any complications.

### Final Outcome

**Patients with DAVFs:** Seven patients had good outcome,

4 patients had moderate outcome, and 2 patients had poor outcome.

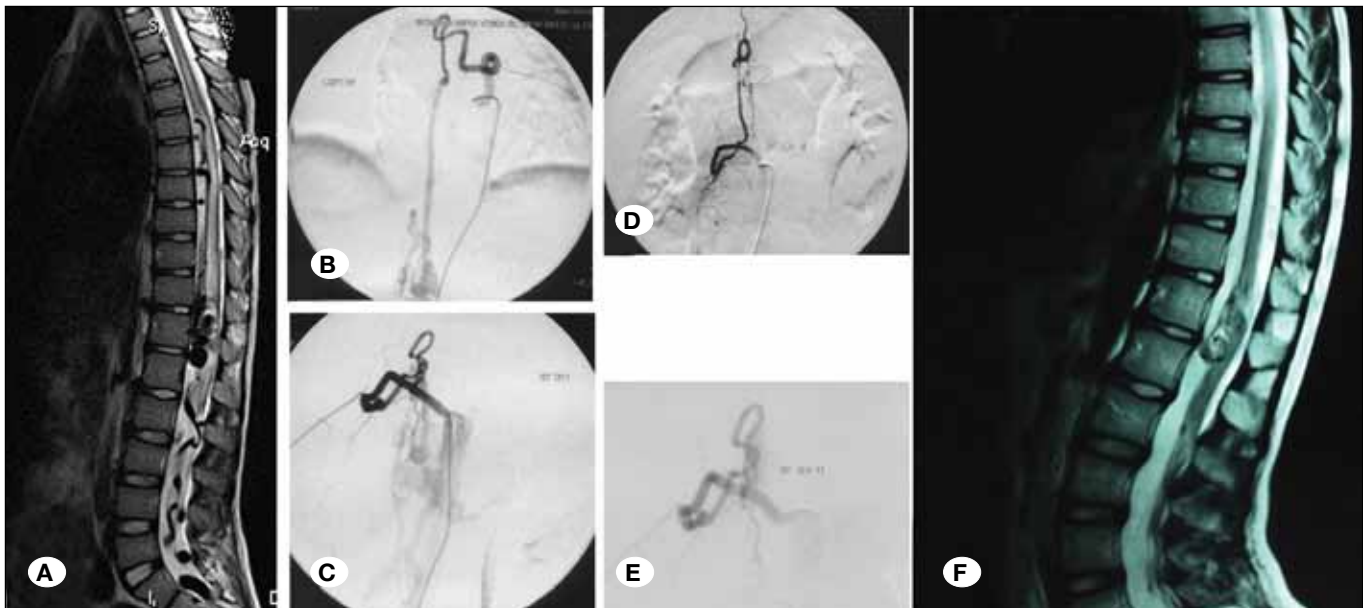
**Patients with PMAVFs:** Five patients had good outcome, one patient had moderate outcome, and one patient was symptomatic with only back pain, but did not receive treatment.

Clinical outcome was assessed in relation to various factors including preoperative neurological condition according to ALS, fistula type, duration of symptoms before intervention, type of intervention and anatomic level of the fistula. Significant correlation of the outcome was found in relation to the duration of symptoms before intervention ( $p=0.012$ ) and preoperative clinical condition ( $p=0.001$ ). The other factors showed insignificant correlation ( $p\geq 1$ ). In patients with PMAVFs, a greater tendency for recovery was noticed, but without statistical significance.

Sphincter disturbances showed a tendency for improvement in patients with PMAVFs more than in patients with DAVFs. Of the 7 patients who suffered from DAVFs and had sphincter disturbances, only 2 recovered, while 4 patients with perimedullary fistula who suffered from sphincter disturbances showed full recovery.

### Treatment Complications

**Patients with DAVFs:** In this group none of the patients who were managed by endovascular embolization had complications related to the treatment procedure itself. However, one patient (patient 5) from the surgically treated



**Figure 2:** (Patient 14) 10-year-old male patient who suffered from sudden onset of paraplegia (ALS 5), MRI (A) was done and it showed spinal cord hemorrhage in the conus medullaris, with edema and swelling of the cord and signal voids on the ventral surface of the cord and going down to the cauda equina. Patient was referred from spinal angiography (B,C) which showed a large ventral perimedullary fistula at the conus medullaris supplied by the anterior spinal artery with a large nidal aneurysm that was probably the cause of the hemorrhage; the patient was managed by endovascular embolization with glue and coils and the fistula was excluded totally (D,E) in one session. One-year follow-up showed a marvelous improvement of the patient; the patient can walk independently with minor support with grade 4 weakness only (ALS 3); follow-up MRI (F) showed resolution of the cord edema and the signal voids while the shadow of the aneurysm filled with the embolic material could still be detected.

group suffered from cerebrospinal fluid (CSF) leak, which lead to intracranial hypotension and presented with chronic subdural hematoma (SDH) one month after his surgery and was managed by surgical evacuation.

**Patients with PMAVFs:** Patient 17 (Figure 3A-I) was operated upon for dorsal perimedullary fistula type A fistula. Initially, the fistula was surgically disconnected but the patient did not show any improvement. An MRI was done showing no resolution of the spinal cord edema and hyperintensity. Further angiography showed recanalization of the fistula and another surgery was therefore done for excision of the fistula. The patient experienced some improvement after the second surgery but later on she presented with paraparesis and sphincter disturbance. MRI showed arachnoid cyst compressing the spinal cord. The patient was operated for a third time to remove the cyst. Post-operatively there was residual weakness but with resolution of pain and improvement of sphincter disturbances.

## DISCUSSION

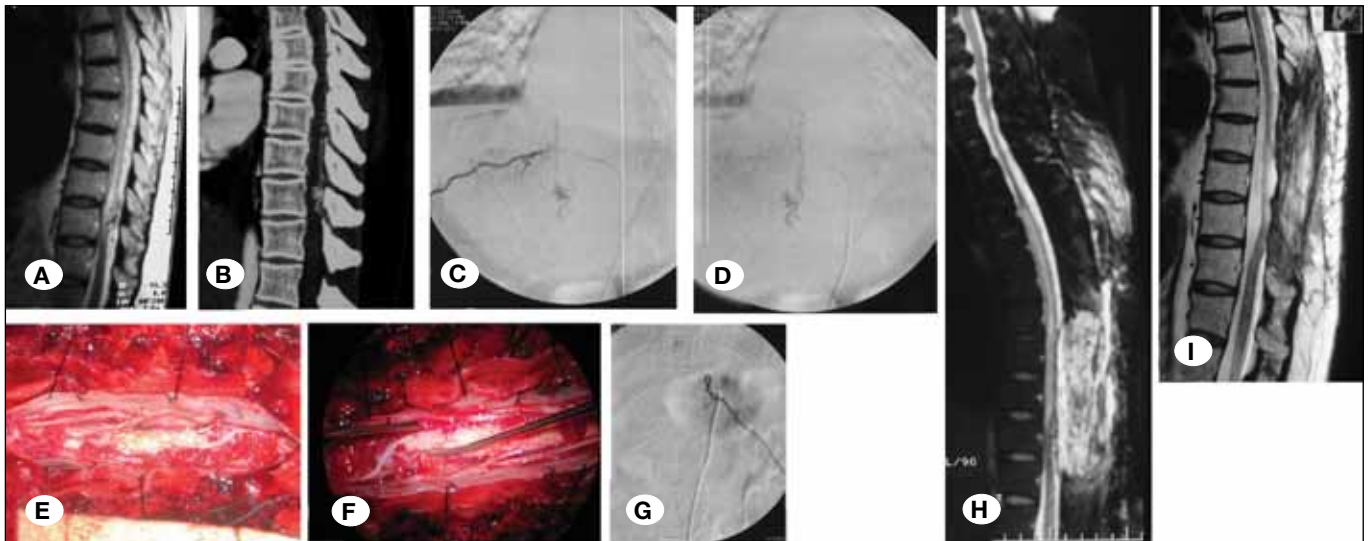
Spinal vascular malformations were previously classified by Lasjaunias et al.(31,32), Spetzler et al.(16,18) and many others (12,19). These lesions include direct fistulas, nidal type AVMs,

aneurysms, and mixed lesions in different locations in relation to the spinal cord.

Three types of direct AVFs were recognized among the spinal vascular malformations:

1. Spinal epidural fistulas (not included in our series)(22).
2. Spinal dural arteriovenous fistulas (Type I): These are dorsally located fistulas that arise from a radicular artery. They are classified into single or multiple feeder shunts (12,19).
3. Spinal perimedullary fistulas (Type IV): These can be ventral arising from the anterior spinal artery, or dorso-lateral arising from the posterior spinal arteries. Also perimedullary fistulas are classified according to size of the shunt into A, small shunt; B, medium shunt; and C, large shunt (12,19).

The direct fistula between the radicular artery and vein at the dura of dorsal nerve root are type I malformation (SDAVFs) and they represent 80% of all lesions (14,17-19,24,25,28). They usually affect males over 40 years and are usually idiopathic but surgery and trauma can be the predisposing factor in some cases (3,8,10,17,27,33).



**Figure 3:** (Patient 13) 52-year-old female patient who over the course of 2 years had suffered from progressive spastic paraparesis and sphincter disturbances along with back pain; examination showed her to have Grade 3 motor power in both lower limbs with sensory level at D10 dermatome. MRI (A) showed cord edema and expansion in the form of T2 hyper-intensity with peripheral hypo-intensity, along with signal voids. She had CT angiography of the spine (B) which showed a dorsally located fistula opposite to D10 vertebral body supplied by the posterior spinal artery. This was confirmed by spinal angiography (C,D), which showed the fistula to be a dorsally located perimedullary spinal AVF. Treatment was attempted by surgery; surgery was done via a posterior approach with laminectomy from D8 to D11 and opening of the dura in a midline fashion. The fistula was observed along the posterolateral aspect of the cord (E) with engorged tortuous veins draining it. Disconnection was attempted via bipolar cautery of the posterior spinal artery connection to the fistulous point. The veins immediately showed a degree of pallor denoting successful disconnection (F). Following surgery, the patient showed persistence of symptoms and spinal angiography done 3 months later showed recanalization of the fistula from the lower radicular segment (not shown). She was operated once again and this time excision of the whole fistula was done instead of simple disconnection. Post-operative spinal angiography showed complete angiographic cure of the fistula but the patient condition remain in stationary clinical course (G). Three months follow-up MRI after second surgery showed an arachnoid cyst complicating the surgical site (H), which caused cord tethering and progressive weakness. The patient was re-operated to excise the arachnoid cyst and untether the cord. Final MRI (I) showed successful removal of the cyst with resolution of the cord edema and signal voids.

A fistulous connection between the anterior or posterior spinal arteries and paraspinal veins constitutes PMAVF and accounts for 17-35% of spinal vascular malformations (14,18,23,28). They usually occur in young patients and mostly in second or third decade, and therefore the etiology is thought to be congenital (3,8,17,27).

The clinical manifestations of SDAVFs are often progressive upper motor weakness of the lower limb in most patients, numbness, pain sphincter disturbances and sexual dysfunction (10,17,19,21,27). The underlying pathophysiological mechanisms result from shunting of high-pressure arterial blood into the spinal veins, leading to arterial steal, ischemia, venous congestion and progressive spinal cord necrosis (14,27,36). Acute neurological deterioration can occur due to hemorrhage from the fistula, or thrombosis of the pathological veins, which is known as the "Foix-Alajouanine syndrome" (3,5,14,18,20,27,29).

The risk of rupture and hemorrhage is higher in the perimedullary than the dural type due to higher hemodynamics, flow-related aneurysms, and larger venous varices that can cause acute worsening of symptoms and also compressive symptoms in some cases (3,5,7,14,18,20,29).

Regarding these series, the choice for treatment was multifactorial. Beside the type of the fistula and its location, certain economic factors restricted endovascular treatment for some patients and surgical treatment was therefore a valid choice in these cases. Also rates of success and recurrence were also important factors as well as the ventral versus dorsal location of the fistulas.

SDAVF being dorsally located with slow hemodynamics, the preferred treatment was surgical disconnection via the traditional posterior approach. After opening the dura, the draining vein is disconnected at the dorsal root dural sleeve (6,8). Hemodynamic changes were observed through color changes and confirmed by ultrasound Doppler. Successful fistulous disconnection is determined when no arterialized blood is seen within the spinal veins (15).

Success rate for endovascular therapy of SDAVF varies between 25% and 75%, while that for surgery can be up to 98% (30,32,35,37,38) with a recurrence rate between 40% and 70% (28,37,38). Surgery is therefore the gold standard for managing SDAVF, except multiple fistulas or patients in poor general condition.

Endovascular embolization was used in the management of 3 patients with SDAVF in this series. One patient had angiographic cure, the second patient was re-embolized and the third patient underwent surgical disconnection due to failed endovascular obliteration.

Management of PMAVFs is more demanding than SDAVFs. Surgery for a PMAVF is somewhat more challenging because of the anatomical location and involvement of the anterior or posterior spinal arteries in their formation (4,28). Perimedullary fistulas are classified into types A, B and C depending on the size of the fistula, which should be considered in their management along with the anatomical location, whether ventral or dorsolateral (4,16,28).

Recent advances in endovascular techniques and materials have allowed replacement of the complex and risky microsurgery of PMAVFs by endovascular embolization. Endovascular embolization is preferred for these lesions nowadays (11,27).

In this series, only one patient with dorsally located PMAVM was managed by surgery in the perimedullary fistula group (patient 16, Figure 3A-I). All other patients were successfully managed using different endovascular techniques using coils and glue (NBCA). Angiographic cure was obtained in all patients.

Clinical outcome after intervention of a spinal fistula is difficult to predict. Currently, there are no established predictive factors of clinical outcome. It is difficult to assess the prognosis of every patient after intervention as regards to when and how much he will improve. Anatomical or angiographic cure of spinal fistula does not mean clinical cure in all cases and only two thirds of all patients showed improvement of their motor symptoms and one third showed improvements of other symptoms such as sensory disturbances, pain, impotence and sphincter disturbances (7,10,13,17,37).

In this series, perimedullary fistulas showed a tendency for recovery more than SDAVFs after angiographic eradication of the fistula. Out of 7 treated patients with perimedullary fistula, 6 showed recovery or good improvement, while in the dural spinal fistula group, only 7 patients showed change from pre-operative neurological condition, while 6 patients experienced only arrest of the disease progression. However, statistical significance could not be reached ( $p=0.329$ ).

From the reported series in the literature, it seems that the most important factors affecting the outcome after successful treatment are the pre-operative neurological condition and the age of the patient (1,6,7,10,21,27,34). In our series, there was a significant relationship ( $p=0.001$ ) between the preoperative neurological condition and outcome and fortunately some poor grade patients improved. It is important to interfere in all symptomatic patients, even paraplegic ones (1). In our series, 6 patients in bad neurological condition (two were paraplegic) improved significantly (for ALS grade 4 and 5 to grade 0). There was tendency to improve in younger age, but this was statistically insignificant ( $p=0.642$ ). The same was found in the study of Schuss et al. (34).

In our series, the shorter the time to intervention the better was the outcome. All patients treated in less than 3 months from the onset of symptoms improved ( $p=0.012$ ). In some previous series, the duration of symptoms before intervention failed to show a significant correlation with postoperative outcome (7,6,21). In others, there was significant improvement with earlier intervention from the onset of symptoms (13,26). Aghakhani et al. (1) had a series of paraplegic patients with SDAVFs treated within 3 months that improved significantly.

Reports of the outcome of perimedullary fistulas are poor in the literature (3,17). Improvement of the motor symptoms was observed more than sphincteric control. The outcome of perimedullary fistulas versus dural fistulas is not clearly determined in the literature. However, we believe that



perimedullary fistulas have better outcome than the dural type as shown in the results of this series but the small number of cases has impacted the statistical power and further studies with larger series are therefore needed to support or deny this hypothesis.

Successful treatment of spinal fistulas depends on early clinical detection, proper investigation, and proper interpretation of MRI followed by good and detailed angiographic studies. The rarity of these lesions in relation to other spinal pathologies usually delays the diagnosis of the affected patients.

For SDAVF, surgery is the first option for treatment, unless the patient prefers endovascular treatment or the poor medical condition of the patients becomes a barrier to safe surgery. The key for successful treatment is disconnection of the draining vein.

For PMAVF, if the fistula is ventrally located, endovascular treatment is usually the first choice. If it is a dorsal perimedullary fistula, surgery is feasible but intra-operative angiography is necessary in surgery of posterior perimedullary fistulas in order to confirm full eradication of the fistula.

## ■ CONCLUSION

Microsurgery was preferred for dural and dorsally located perimedullary fistulas, while embolization was preferred for ventrally located ones. Clinical improvement was significantly correlated to early intervention and preoperative neurological condition. The age of the patient, fistula type, fistula location, and type of intervention did not show a significant relation with the outcome. Patients could benefit from intervention even if they present with poor neurological condition.

## ■ REFERENCES

- Aghakhani N, Parker F, David P, Lasjaunias P, Tadie M: Curable cause of paraplegia: Spinal dural arteriovenous fistulae. *Stroke* 39: 2756-2759, 2008
- Aminoff MJ, Logue V: The prognosis of patients with spinal vascular malformations. *Brain* 97:211-218, 1974
- Antonietti L, Sheth SA, Halbach VV, Higashida RT, Dowd CF, Lawton MT, English JD, Hetts SW: Long-term outcome in the repair of spinal cord perimedullary arteriovenous fistulas. *AJNR Am J Neuroradiol* 31:1824-1830, 2010
- Atkinson JLD, Piepgras DG: Surgical treatment of spinal cord arteriovenous malformations and arteriovenous fistulas. *Semin Cerebrovasc Dis Stroke* 2:201-208, 2002
- Casasco A, Guimaraens L, Senturk C, Cotroneo E, Gigli R, Theron J: Endovascular treatment of cervical giant perimedullary arteriovenous fistulas. *Neurosurgery* 70:141-149, 2012
- Cecchi PC, Musumeci A, Faccioli F, Bricolo A: Surgical treatment of spinal dural arterio-venous fistulae: Long-term results and analysis of prognostic factors. *Acta Neurochir (Wien)* 150:563-570, 2008
- Cenzato M, Versari P, Righi C, Simionato F, Casali C, Giovanelli M: Spinal dural arteriovenous fistulae: Analysis of outcome in relation to pretreatment indicators. *Neurosurgery* 55:815-822, 2004
- Cho KT, Lee DY, Chung CK, Han MH, Kim HJ: Treatment of spinal cord perimedullary arteriovenous fistula: Embolization versus surgery. *Neurosurgery* 56:232-241, 2005
- Clarke MJ, Patrick TA, White JB, Cloft HJ, Krauss WE, Lindell EP, Piepgras DG: Spinal extradural arteriovenous malformations with parenchymal drainage: Venous drainage variability and implications in clinical manifestations. *Neurosurg Focus* 26:E5, 2009
- Fugate JE, Lanzino G, Rabinstein AA: Clinical presentation and prognostic factors of spinal dural arteriovenous fistulas: An overview. *Neurosurg Focus* 32:E17, 2012
- Giese A, Winkler PA, Schichor C, Kantelhardt SR, Boeckh-Behrens T, Tonn JC, Rohde V: A transmedullary approach to occlusion of a ventral perimedullary arteriovenous fistula of the thoracic spinal cord. *Neurosurgery* 66: 611-615, 2010
- Heros RC, Debrun GM, Ojemann RG, Lasjaunias PL, Naessens PJ: Direct spinal arteriovenous fistula: A new type of spinal AVM. Case report. *J Neurosurg* 64: 134-139, 1986
- Inagawa S, Yamashita S, Hiramatsu H, Kamiya M, Tanaka T, Sakahara H, Aoyama H: Clinical results after the multidisciplinary treatment of spinal arteriovenous fistulas. *Jpn J Radiol* 31:455-464, 2013
- Jahan R, Vinuela F: Vascular anatomy, pathophysiology and classification of spinal vascular malformations of the spinal cord. *Semin Cerebrovasc Dis Stroke* 2:186-200, 2002
- Kataoka H, Miyamoto S, Nagata I, Ueno Y, Hashimoto N: Intraoperative microdoppler monitoring for spinal dural arteriovenous fistulae. *Surg Neurol* 52:466-472, 1999
- Kim LJ, Spetzler RF: Classification and surgical management of spinal arteriovenous lesions: Arteriovenous fistulae and arteriovenous malformations. *Neurosurgery* 59:S195-201, 2006
- Krings T, Thron AK, Geibprasert S, Agid R, Hans FJ, Lasjaunias PL, Reinges MH: Endovascular management of spinal vascular malformations. *Neurosurg Rev* 33(1):1-9, 2010
- Liu A, Gobin P, Riina H: Endovascular surgery for vascular malformations of the spinal cord. *Oper Tech Neurosurg* 6:163-170, 2003
- Martin NA: Surgical treatment of spinal arteriovenous malformations. *J Stroke Cerebrovasc Dis* 6: 287-291, 1997
- McDougall CG, Deshmukh VR, Fiorella DJ, Albuquerque FC, Spetzler RF: Endovascular techniques for vascular malformations of the spinal axis. *Neurosurg Clin N Am* 16:395-410, 2005
- Nagata S, Morioka T, Natori Y, Matsukado K, Sasaki T, Yamada T: Factors that affect the surgical outcomes of spinal dural arteriovenous fistulas. *Surg Neurol* 65(6):563-568, 2006
- Nakagawa I, Park HS, Hironaka Y, Wada T, Kichikawa K, Nakase H: Cervical spinal epidural arteriovenous fistula with coexisting spinal anterior spinal artery aneurysm presenting as subarachnoid hemorrhage-case report. *J Stroke Cerebrovasc Dis* 23:461-465, 2014

23. Narvid J, Hetts SW, Larsen D, Neuhaus J, Singh TP, McSwain H, Lawton MT, Dowd CF, Higashida RT, Halbach VV: Spinal dural arteriovenous fistulae: Clinical features and long-term results. *Neurosurgery* 62(1):159-166, 2008
24. Nishio A, Ohata K, Takami T, Nishikawa M, Hara M: Atypical spinal dural arteriovenous fistula with supply from the lateral sacral artery. *J Clin Neurosci* 14(1):65-68, 2007
25. Nogueira RG, Dabus G, Rabinov JD, Ogilvy CS, Hirsch JA, Pryor JC: Onyx embolization for the treatment of spinal dural arteriovenous fistulae: Initial experience with long-term follow-up. Technical case report. *Neurosurgery* 64:E197-198, 2009
26. Ofran Y, Yovchev I, Hiller N, Cohen J, Rubin SA, Schwartz I, Meiner Z: Correlation between time to diagnosis and rehabilitation outcomes in patients with spinal dural arteriovenous fistula. *J Spinal Cord Med* 36:200-206, 2013
27. Oldfield EH: Surgical treatment of spinal dural arteriovenous fistulas. *Semin Cerebrovasc Dis Stroke* 2:209-226, 2002
28. Oran I, Parildar M, Derbent A: Treatment of slow-flow (type I) perimedullary spinal arteriovenous fistulas with special reference to embolization. *AJNR Am J Neuroradiol* 26: 2582-2586, 2005
29. Patsalides A, Knopman J, Santillan A: Endovascular treatment of spinal arteriovenous lesions: Beyond the dural fistula. *AJNR Am J Neuroradiol* 32(5):798-808, 2011
30. Rodesch G, Hurth M, Alvarez H, David P, Tadie M, Lasjaunias P: Embolization of spinal cord arteriovenous shunts: Morphological and clinical follow-up and results-review of 69 consecutive cases. *Neurosurgery* 53(1):40-49, 2003
31. Rodesch G, Hurth M, Alvarez H, Tadie M, Lasjaunias P: Spinal cord intradural arteriovenous fistulae: Anatomic, clinical, and therapeutic considerations in a series of 32 consecutive patients seen between 1981 and 2000 with emphasis on endovascular therapy. *Neurosurgery* 57(5):973-983, 2005
32. Rodesch G, Lasjaunias P: Spinal cord arteriovenous shunts: From imaging to management. *Eur J Radiol* 46(3):221-232, 2003
33. Saladino A, Atkinson JL, Rabinstein AA, Piepgras DG, Marsh WR, Krauss WE, Kaufmann TJ, Lanzino G: Surgical treatment of spinal dural arteriovenous fistulae: A consecutive series of 154 patients. *Neurosurgery* 67(5):1350-1357, 2010
34. Schuss P, Daher FH, Greschus S, Vatter H, Güresir E: Surgical treatment of spinal dural arteriovenous fistula: Management and long-term outcome in a single-center series. *World Neurosurg* 83(6):1002-1005, 2015
35. Sivakumar W, Zada G, Yashar P, Giannotta SL, Teitelbaum G, Larsen DW: Endovascular management of spinal dural arteriovenous fistulas. A review. *Neurosurg Focus* 26(5):E15, 2009
36. Song D, Garton HJ, Fahim DK, Maher CO: Spinal cord vascular malformations in children. *Neurosurg Clin N Am* 21(3):503-510, 2010
37. Steinmetz MP, Chow MM, Krishnaney AA, Andrews-Hinders D, Benzel EC, Masaryk TJ, Mayberg MR, Rasmussen PA: Outcome after the treatment of spinal dural arteriovenous fistulae: A contemporary single-institution series and meta-analysis. *Neurosurgery* 55(1):77-87, 2004
38. Van Dijk JM, TerBrugge KG, Willinsky RA, Farb RI, Wallace MC: Multidisciplinary management of spinal dural arteriovenous fistulas: Clinical presentation and long-term follow-up in 49 patients. *Stroke* 33(6):1578-1583, 2002