



DOI: 10.5137/1019-5149.JTN.17142-16.2

Received: 28.01.2016 / Accepted: 04.03.2016

Published Online: 26.04.2016

Original Investigation

Transcortical Removal of Third Ventricular Colloid Cysts: Comparison of Conventional, Guided Microsurgical and Endoscopic Approaches and Review of the Literature

Pulat Akin SABANCI¹, Yavuz ARAS¹, Ahmet ALI², Tugrul Cem UNAL¹, Duygu DOLEN¹, Serra SENCER³, Nail IZGI¹, Faruk UNAL¹, Orhan BARLAS¹

¹Istanbul University, Istanbul School of Medicine, Department of Neurosurgery, Istanbul, Turkey

²Istanbul University, Istanbul School of Medicine, Department of Anesthesiology, Istanbul, Turkey

³Istanbul University, Istanbul School of Medicine, Department of Radiology, Istanbul, Turkey

ABSTRACT

AIM: To compare the clinical results of different transcortical approaches for the removal of third ventricular colloid cysts (CC).

MATERIAL and METHODS: Records of 41 colloid cyst patients who underwent transcortical conventional microsurgical, microsurgical with the aid of stereotactically guided cylindrical retractor (minitubular), and endoscopic removal between 1999 and 2015 were retrospectively analyzed. The clinical results of these three different transcortical surgical approaches were compared and a literature review of published series was conducted.

RESULTS: Ages ranged between 16 and 66 years (mean: 36.8). There were 18 female and 23 male patients. Headache was the main presenting symptom. The mean CC diameter was 15.5 mm. Intraventricular hemorrhage was encountered in 2 patients. Three patients needed postoperative ventriculoperitoneal shunt surgery. Postoperative seizures were seen in 3, postoperative neurological deficit in 3 and residual tumor in 2 patients. The conventional approach resulted in significantly higher rates of postoperative seizure compared to the minitubular and endoscopic approaches ($p=0.012$). The rate of residual cyst was significantly higher in endoscopic approach compared to conventional and minitubular approaches ($p=0.024$). Conventional approach led to significantly higher rates of neurological deficit compared to the two other approaches ($p<0.05$).

CONCLUSION: With respect to complication rates, the stereotactic and endoscopic approaches are both safe and reliable compared to conventional microsurgical approach that has unacceptably high rates of seizures and neurological deficit. Concerning completeness of removal, both microsurgical approaches are by far superior to neuroendoscopy. The stereotactic microsurgical approach compares favorably in both respects with endoscopic and conventional microsurgical approaches.

KEYWORDS: Colloid Cyst, Third Ventricle, Surgical Treatment, Microsurgery, Neuroendoscopy, Stereotaxy, Tubular System

INTRODUCTION

Third ventricular colloid cysts (CC) are rare tumors that constitute 0.5-2% of intracranial (20,23) and 15-20% of intraventricular tumors (31). These non-neoplastic lesions are believed to arise from misplacement of endodermal tissue in the anterosuperior portion of the third ventricle during

development of the central nervous system (35). Although colloid cysts are benign tumors, they may continue to enlarge to occlude the foramen of Monro and are known to lead to sudden death (9,21,39).

Standard surgical approaches for the removal of CC traverse either the corpus callosum or the frontal cortex.



Corresponding author: Pulat Akin SABANCI

E-mail: sabanci.akin@gmail.com

The conventional transcortical approach has been reported to result in high seizure rates due to parenchymal injury (8,12,13). The transcallosal approach may not lead to seizures, but the risks of both venous infarction and interhemispheric disconnection syndrome are significant (19,33,43). To counter these problems, less invasive transcortical approaches were developed to reduce neuronal damage in the frontal lobe. Cortical incision and parenchymal dissection were minimized by the use of stereotactically guided cylindrical retractor (4,6,25). Cortical injury was further reduced by the introduction of the neuroendoscope (14,18,21,22,28,30,46).

We present a retrospective review of our transcortically operated cases of colloid cyst and a review of the literature to see whether this progressive reduction in the size of the cortical incision and related parenchymal injury over the last 15 years was reflected in the clinical results of CC removal.

■ MATERIAL and METHODS

The data of 41 patients, who were operated for CC between the years 1999 and 2015 at the Department of Neurosurgery Istanbul University, were retrospectively reviewed. Eleven patients underwent resection of CC by conventional microsurgical transventricular transforaminal approach (conventional approach), 21 patients with the microsurgical transventricular transforaminal approach via a stereotactically guided cylindrical retractor (minitubular approach), and nine patients with the endoscopic transfrontal approach (endoscopic approach). Age, sex, signs and symptoms on admission, duration of symptoms, computerized tomography (CT) and magnetic resonance imaging (MRI) details, maximal CC diameter measured in millimeters on MRI, need for ventriculostomy (preoperative or postoperative), the surgical approach, surgical complications, shunt dependency, follow-up period (in months), presence of residual cyst, and any recurrence were noted. Surgery was offered when a CC had a diameter greater than 10 mm or caused hydrocephalus, whether or not it was symptomatic. This study includes only those patients that underwent surgery. Current modified Rankin Score of patients were determined by clinical examination or telephone interviews (36). Histopathological diagnosis of CC was available for all patients. Clinical results of the three surgical approaches were compared with each other, and with the results of our literature review.

Operative Technique

Surgical approach was selected according to surgeons' preference. Both conventional and minitubular approaches were performed via a frontal craniotomy placed just anterior to the coronal suture. Conventional approaches were performed freehand, without the use of neuronavigation. Minitubular approach, introduced independently by the senior author, is described in detail elsewhere (4). Briefly, a cylindrical retractor 14 mm in diameter is placed in the instrument holder of the Leksell® stereotactic frame (Elekta AB, Stockholm, Sweden) and directed to the target, for which a point in the frontal horn just lateral to the foramen of Monro was chosen, and the cyst removed microsurgically through the retractor. The endoscopic

approach was conducted via a standard neuroendoscope working with a single instrument technique having a 0° view angle with a 2.7 mm channel diameter and 185 mm working length (Richard Wolf GmbH®, Knittlingen, Germany). All endoscopic cases were performed in pure endoscopic fashion. In none of the cases was an endoscope-assisted approach used. The endoscopic approaches were performed through a single burrhole (Figure 1A-C). The maximal diameter of craniotomy was 6 cm for conventional and 4 cm for minitubular approaches. The length of cortical incisions were 20-30 mm in conventional, 10-14 mm in minitubular and 4-6 mm in endoscopic approaches (Figure 2A-C).

Statistical Analysis

Distribution of quantitative data was evaluated using the Kurtosis and Skewness tests. Data are presented as mean ± standard deviation for normally distributed quantitative and as median and minimum-maximum where the quantitative data were not normally distributed. Qualitative data are presented as number of cases. Statistical analyses performed were: Student-T test, ANOVA test, Tukey subgroup test for comparison of normally distributed quantitative variants and Mann-Whitney U test, Kruskal-Wallis test for comparison of not normally distributed quantitative variants. Chi-square test was used to compare qualitative variants. Cramer's V correlation test was used to assess correlations between meningitis and shunt dependency (Qualitative data). $p < 0.05$ was considered as statistically significant. Statistical analyses were carried out using SPSS for Windows version 15.0 (SPSS Inc. Chicago, IL, USA).

Literature Review

Surgical series of colloid cysts with more than ten patients published between 1989 and 2015 were reviewed and series containing patients operated with conventional transfrontal microsurgical, microsurgical with stereotactically guided cylindrical retractor and transfrontal endoscopic approaches were included in this study. Patients operated via the transcallosal approach or series containing only non-hydrocephalic patients (45) were excluded. The data extracted from the reports included the surgical technique, total number of patients, age, sex, presence of hydrocephalus, cyst diameter, conversion to craniotomy, residual tumor, shunt dependency, intraventricular hemorrhage, infection, postoperative seizure, permanent neurological deficit, mortality and follow-up period. Seizure, permanent neurological deficit and completeness of resection rates were compared in the three surgical approach groups.

■ RESULTS

Clinical Features

Ages ranged between 16 and 66 years (mean: 36.8). There were 18 female and 23 male patients. Headache was the most common presenting symptom. Other presenting symptoms of the patients are listed in Table I. Six patients that were comatose on admission underwent pre-operative external ventricular drainage, which was unable to reverse the fatal

clinical course in only one (Patient 11) of these six patients. One patient (Patient 23) had been operated for shunt surgery elsewhere before being referred to our clinic for CC resection

Table I: Presenting Symptoms of the Patients

Symptoms	Number of Patients	(%)
Headache	30	73
Confusion	7	17
Nausea/Vomiting	6	15
Coma	6	15
Dizziness	4	10
Gait disturbance	3	7
Visual disturbance	2	5
Incontinence	2	5
Amnesia	2	5
Parkinsonism	1	2

surgery. Clinical and radiological details of the patients are summarized in Table II. There was no statistically significant difference between the three different surgical approaches in terms of patient’s age, sex and CC diameter ($p>0.05$). Detailed data are given in Table III.

Radiological Investigations

Preoperative CT or MRI examinations were available for all patients, and 39 patients had both (Figure 3A-F). One patient who was comatose on admission was operated without MRI. All patients had follow-up radiological studies; either CT or MRI or both. The mean CC diameter was 15.5 mm (range: 7-23 mm) for the entire cohort. Mean diameters for each different approach are given in Table III. All patients but one (Patient 37) had ventricular enlargement preoperatively. Patient 37, who was referred to us for the removal of a pituitary adenoma, underwent endoscopic removal of a concomitant CC diagnosed incidentally.

Complications

Intraventricular hemorrhage was encountered in two patients, one in conventionally and the other in endoscopically operated groups. In the latter patient, endoscopy was converted

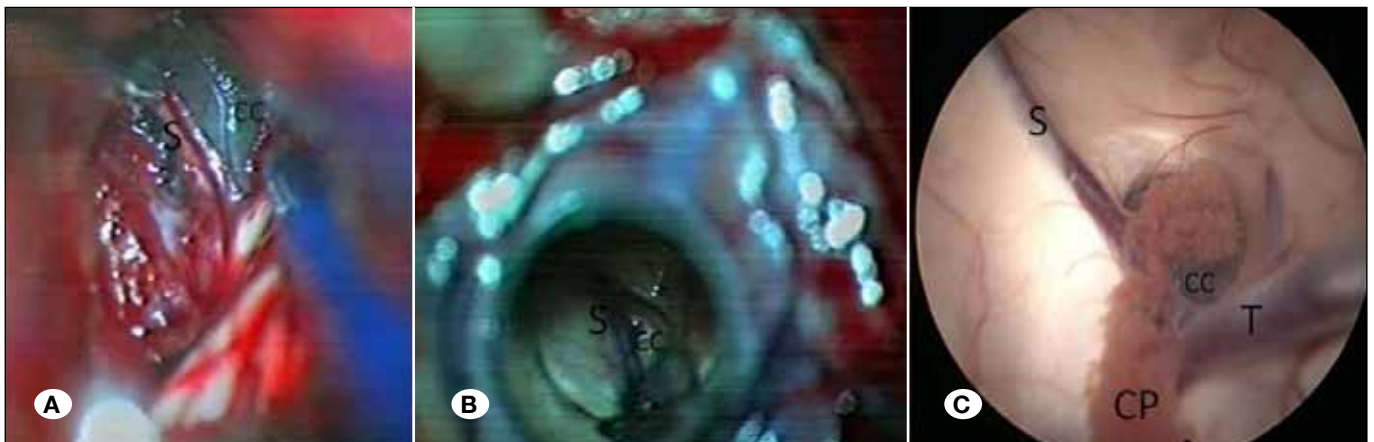


Figure 1: Intraoperative views of three different approaches; **A)** Conventional, **B)** Minitubular, **C)** Endoscopic (**CC:** Colloid cyst, **CP:** Choroid plexus, **S:** Septal vein, **T:** Thalamostriate vein).

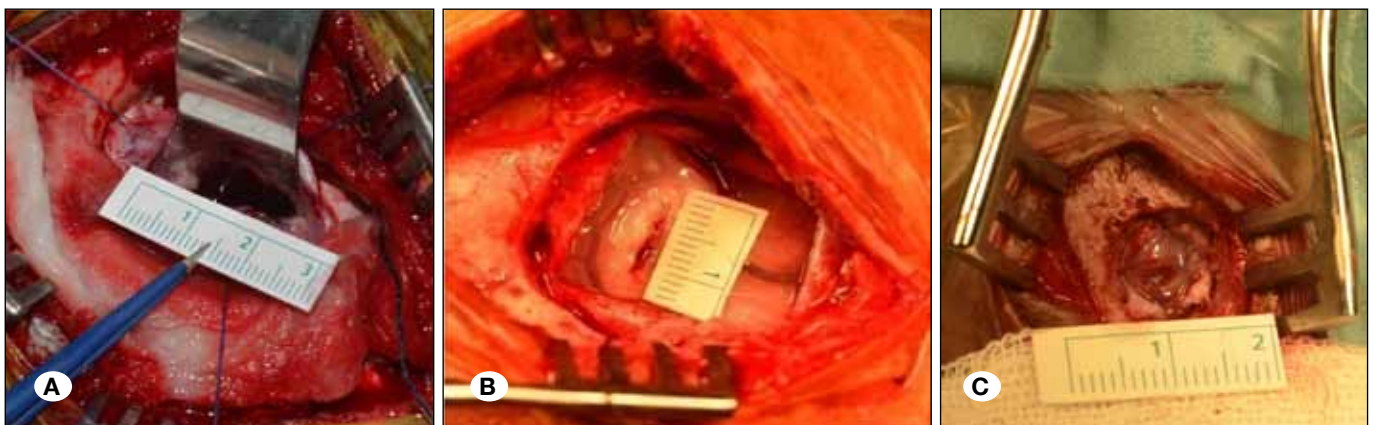


Figure 2: Photographs of cortical incisions in different lengths specific to the approaches **A)** Conventional approach, **B)** Minitubular approach, **C)** Endoscopic approach.

Table II: Clinical and Radiological Details of the Patients

Pat No	Age (y)/ Sex	Symptom	Duration	Previous Procedure	Preop MR-T1w (Intensity)	Preop CT * (Density)	Cyst Dia	Vent. drain.	Surgical approach	Complication	Rankin Score	FU* (mo)
1	34,F	HA, N/V	10d	-	Hyper	Hyper	12	-	Con	-	0	170
2	48,M	HA	2w	-	Hyper	Hyper	15	-	Con	-	0	160
3	18,M	HA	1y	-	Iso	-	12	-	Con	Contusion, infarct, hemiparesis, seizure	4	143
4	39,M	HA, C	3 d	-	Hyper	Hyper	15	Postop (x2)	Con	IVH, Meningitis, hemiparesis HS-shunt op Reop- shunt	5	124
5	16,M	HA N/V	6m	-	Hyper	Hyper	12	-	Con	-	0	108
6	58,M	HA D	9 m	-	Hyper	Hyper	20	-	Con	Meningitis, seizure	0	87
7	37,F	D	1y	-	Hypo	Hyper	14	-	Con	-	0	70
8	28,M	HA	5m	-	Iso	Hyper	18	-	Con	Seizure	1	65
9	41,F	GD	1 y	-	Hyper	Hyper	12	-	E& Con	During Endoscopy hemorrhagy from cho plexus- IVH, shifted to Con	0	54
10	52,F	HA C, I, A	3y	-	Hyper	Hyper	15	Post-op (x2)	Con	Venous infarction, hemiparesis Meningitis, Shunt op, Shunt dysfunction (reop 2 y later)	2	47
11	40,F	HA N/V LoC	2 d	-	-(emergency)	Iso (14 mm hyper inside)	23	Preop	Con	Ex	6	
12	22,F	LoC	1d	-	Iso	Hyper	18	Preop	MT	-	0	202
13	41,M	LoC	1w	-	Hyper	Hyper	22	Preop	MT	-	0	195
14	26,M	LoC	1y	-	Hyper	Hyper	18	Preop	MT	Meningitis	0	190
15	62,M	P,GD	4m	E	Iso	Hyper	21	-	MT	-	0	186
16	17,M	HA,VD	1m	-	Hyper	Iso	19	-	MT	Closed CSF Fistula	0	173
17	40,M	HA	3y	-	Hypo	Iso	16	-	MT	-	0	172
18	51,M	HA,C	2m	-	Iso	Iso	8	-	MT	-	0	171
19	36,F	HA,GD	3m	-	Hyper	Iso	18	-	MT	-	0	170
20	22,M	LoC	3d	-	Hyper	Iso	17	Preop	MT	-	0	166

Table II: Cont.

21	17,M	HA, diplopia	3w	-	Hypo	Iso	19	-	MT	-	0	165
22	17,F	HA	3w	-	Hypo	Hypo	19	-	MT	-	0	155
23	38,M	HA	4m	Shunt op (3m ago)	Hyper	Hyper	13	-	MT	-	0	140
24	33,M	HA, C	6m	-	Hyper	Hyper	15	-	MT	-	0	139
25	47,M	HA	3w	-	Hyper	Hyper	18	-	MT	-	0	86
26	30,F	HA	3 m	-	Iso	Hyper	7	-	MT	-	0	75
27	60,M	D	4 m	-	Hyper	Hyper	9	-	MT	-	0	68
28	29,F	HA, C	3m	-	Hyper	Hyper	15	-	MT	-	0	55
29	31,F	N/V, C	2 d	-	Iso	Hyper	15	-	MT	Meningitis	0	12
30	66,F	A,I	4 d	-	Hypo	Iso	16	-	MT	EDH under craniotomy (conservative)	0	7
31	42,M	HA, N	10 d	-	Iso	Hyper	22	-	MT	-	0	6
32	20,M	HA,N	2 y	-	Iso	Hyper	11	-	MT	-	0	2
33	26,F	HA, N	2w	-	Iso	Iso	16	-	E	-	0	81
34	48,F	HA, N/V	1 w	-	Hyper	Hyper	18	-	E	-	1	68
35	45,F	HA ,LoC	1 d	-	Hypo	Hyper	15	Preop	E	Meningitis	0	45
36	32,F	HA	10m	-	Hyper	Hyper	9	-	E	-	0	31
37	34,M	Incidental	-	Diagnosed 1 m before (pit. op.)	Hyper	Hyper	13	-	E	Residue	0	24
38	32,F	HA	2 y	-	Hyper	Hyper	16	-	E	Residue, Shunt op	0	20
39	38,M	HA, C	6m	-	Hyper	Hyper	14	-	E	-	0	17
40	52,M	HA, D	3m	-	Iso	Iso	13	-	E	-	0	15
41	45,F	HA	1m	-	Hyper	Hyper	18	-	E	-	0	8

Cyst dia: Cyst diameter in mm, **Preop:** Preoperative, **FU(mo):** Follow-up (months), **HA:** Headache, **N:** Nausea, **V:** Vomiting, **A:** Amnesia, **LoC:** Loss of Consciousness (GCS <8), **I:** Incontinence, **GD:** Gait disturbance, **D:** Dizziness, **C:** Confusion, **P:** Parkinsonism, **VD:** Visual Disturbance, **y:** years, **m:** months, **w:** weeks, **d:** days, **Con:** Conventional approach, **MT:** Minitubular Approach, **Stereotaxy guided Transventricular Microsurgery with a tubular system, E:** Endoscopic, **IVH:** Intraventricular hemorrhage, **pit:** pituitary, **Ex:** Exitus, **- :** none, **M:** Male, **F:** Female, **Vent drain:** Ventricular drainage, **Pat No:** Patient number.

to a conventional approach when the bleeding occurred intraoperatively (Figure 4A-E).

Surgery was complicated by bacterial meningitis in six patients. Patients 4, 10 and 14 and were infected with coagulase-negative Staphylococcus, patient six with methicillin-resistant Staphylococcus aureus, patient 29 with Klebsiella, and patient 35 with Acinetobacter strains. There were no significant differences among surgical approaches in terms of postoperative meningitis ($p=0.380$).

In the postoperative period, three patients required insertion of ventriculoperitoneal shunts. Of those, patient 38 who was

operated via endoscopy had undergone subtotal excision. The other two patients that developed meningitis were both operated via the conventional approach and both had undergone an external ventricular drainage insertion preoperatively. Postoperative shunt dependence was found to be statistically insignificant among surgical groups ($p=0.152$) whereas a correlation was found between meningitis and shunt dependence ($p=0.008$, $V=0.414$).

All patients that were operated for CC had been prescribed antiepileptic drugs (Phenytoin 2x150 mg/day or levitiracetam 2x500 mg/day, orally) for a period of 6 months in the postop-

erative period if seizure free. Three patients (7.3%) (Patient 3, 6 and 8), all of whom were operated via the conventional approach, had postoperative seizures in this series. Two of these were on phenytoin, the third on levatiracetam. After recognition of the seizure, their antiepileptic drug dosages had been increased and no further seizures that needed additional electroencephalography (EEG) investigation occurred. The conventional approach resulted in significantly higher rates of

postoperative seizure compared to the minitubular and endoscopic approaches (p=0.012).

Two patients had postoperative residual cysts. These were patient 37 and 38, both of whom had been operated via the endoscope, and were discharged with no symptoms at all. No other residual cysts were determined in the entire cohort. The rate of residual cyst was significantly higher in the endoscopic

Table III: The Total Number of Patients for Whom the Information was Available is Shown in Parantheses and in the Denominator When Applicable

Type of Surgery	Conventional Approach		Minitubular Approach		Endoscopic Approach		Total
	Literature Review	Present Series	Literature Review	Present Series	Literature Review	Present Series	
Total no patient	91	11	51	21	460	9	643
Mean age (years)	35.6 (61 p)	39	41.8	35.6	42.1	39.1	
Range of age (years)	6-68	18-58	16-71	17-66	9-78	26-52	9-78
Sex (M/F)	48/43	7/4	27/19 (46 p)	13/8	261/199	3/6	359/279 (638 p)
Hydrocephalus	75% (46/61)	100% (11/11)	84% (43/51)	100% (21/21)	80% (369/460*)	89% (8/9)	81% (497/613)
Mean cyst diameter (mm)	15	15.6	17.3 (21 p)	16	13.5 (430 p)	14.4	
Range of diameters (mm)	NA	12-23	8-23	7-22	3-50	9-18	3-50
Length of incision (mm)		20-30		10-14		4-6	
Conversion to craniotomy	NA	NA	NA	NA	3% (8/235)	11% (1/9)	4% (9/244)
Residual tumor	2% (1/61)	0% (0/11)	3% (1/39)	0% (0/21)	28% (115/407)	22% (2/9)	22% (120/548)
Shunt dependency	5% (4/91)	18% (2/11)	10% (5/51)	0% (0/21)	9% (39/442)	11% (1/9)	8% (50/625)
IVH	0% (0/61)	9% (1/11)	0% (0/51)	0% (0/21)	3% (12/460)	11% (1/9)	2% (14/613)
Infection	7% (5/71)	27% (3/11)	4% (2/51)	5% (1/21)	5% (22/460)	11% (1/9)	5% (34/623)
Postoperative seizure	13% (12/91)	27% (3/11)	4% (2/51)	0% (0/21)	0.5% (2/432)	0% (0/9)	3% (19/615)
Permanent neurological deficit	3% (2/61)	27% (3/11)	2% (1/51)	0% (0/21)	6% (26/460)	0% (0/9)	5% (32/613)
Mortality	3% (2/71)	9% (1/11)	0% (0/51)	0% (0/21)	1% (3/460)	0% (0/9)	1% (6/623)
Mean FU period (mo)	45.1 (86 p)	102.8	28.8	120.7	40.6	34.3	
Range of FU		0-170	3-121	2-202	0-147	8-81	0-202

NA: Not applicable, p: patients, mm: milimeters, FU: Follow-up, mo: months, M: male, F: female, IVH: Intraventricular hemorrhage
*Two patients had pre-operative shunt insertion.

approach compared to the conventional and minitubular approaches ($p=0.024$).

Permanent neurological deficits were encountered in three (7.3%) patients: patient 3, 4 and 10. These three patients, all of whom were operated via a conventional approach, remained hemiparetic. Hemiparesis was caused by venous infarction in two and intraventricular hemorrhage in the third patient. In the present series, postoperative disconnection syndrome or memory deficit did not occur in any of the patients. The conventional approach led to significantly higher rates of

neurological deficit compared to the two other approaches ($p<0.05$).

Mortality

Only one patient (Patient 11) succumbed in this series. She was comatose with dilated pupils on admission. Brain CT showed dilated ventricles and diffuse cerebral edema due to a colloid cyst and signs of uncal herniation (Figure 5). Despite an urgent operation following external ventricular drainage, she died.

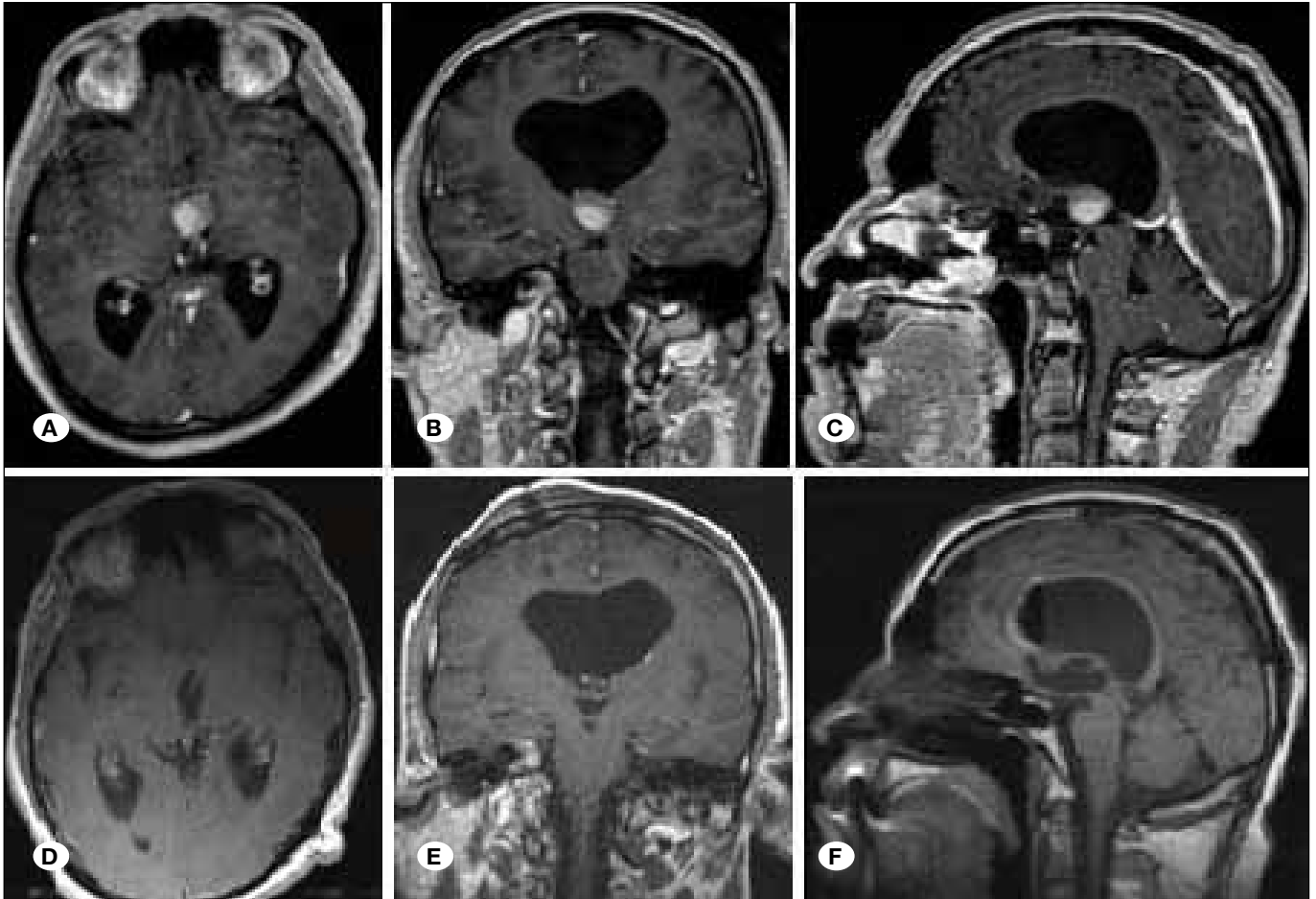


Figure 3: Preoperative (A,B,C) and postoperative (D,E,F) axial, coronal and sagittal T1 W postcontrast MR images of patient 39, show total removal of the colloid cyst located centrally in the foramen of Monro.

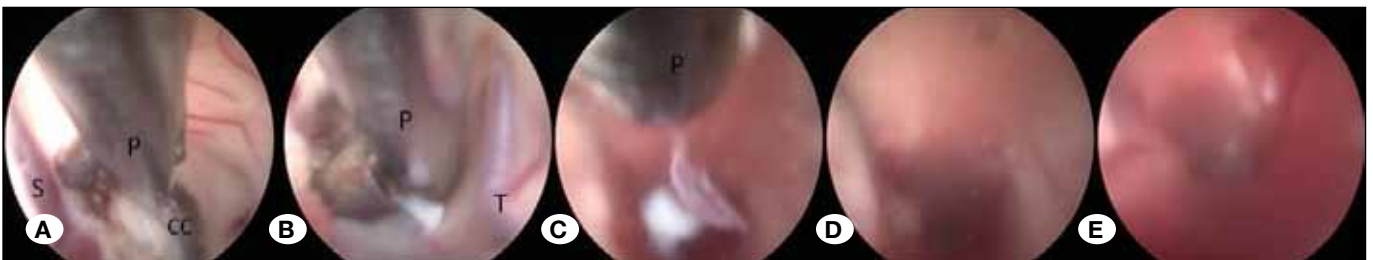

Figure 4A-E: Intraoperative view of intraventricular hemorrhage. A massive bleeding occurred after a part of CC was removed via punch forceps (CC: Colloid cyst, P: Punch forceps, S: Septal vein, T: Thalamostriate vein).

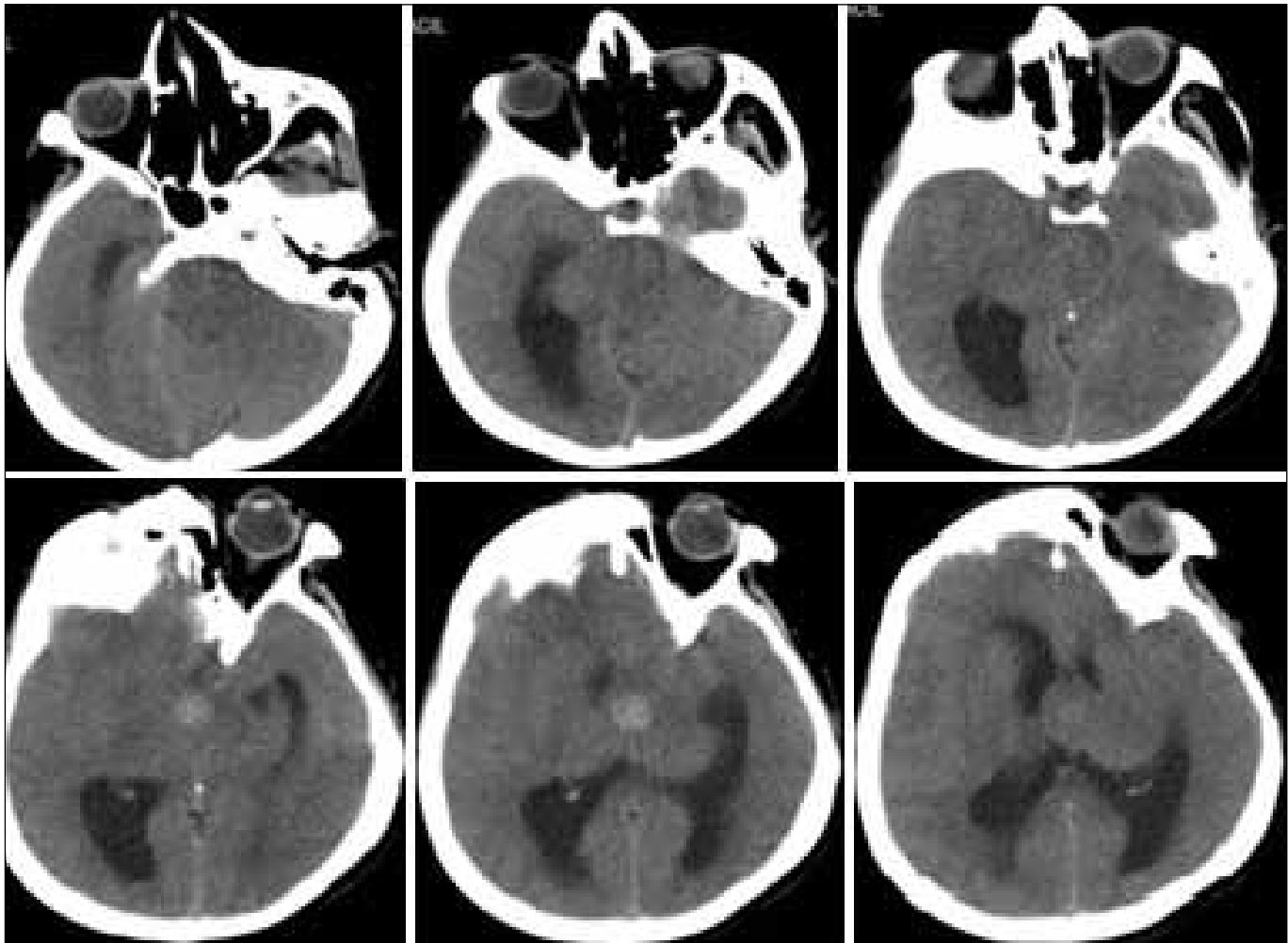


Figure 5: Admission CT of patient 11. A CC with 23 mm diameter (isodense) and 14 mm hyperdense center. The perimesencephalic cisterns could not be identified clearly.

Follow-up

Mean follow-up period was 102.8 months for conventional, 120.7 months for minitubular and 34.3 months for endoscopic approaches (Table III). Six of 11 patients operated via the conventional approach, 21 of 21 patients operated via the minitubular approach, and 8 of 9 patients in the endoscopy group had modified Rankin Scale scores of 0.

Literature Review

The results of our literature review are presented in Table IV. The results of the comparison of the present series with our literature review of 602 patients are summarized in Table III. The mean ages were 35.6, 41.8, 42.1 years in the conventional, minitubular and endoscopic approaches, respectively. Hydrocephalus was present in 75% of conventional, 84% of minitubular and 80% of endoscopic cases. Residual tumor was detected in 2%, 3%, 28% of conventional, minitubular and endoscopic patients, respectively. The rates of postoperative seizure were 13% in conventional, 4% in minitubular and 0.5% in endoscopic cases. A neurological deficit was

found in 3% of patients in conventional, 2% in minitubular and 6% in endoscopic cases (Table III) (1,3-6,8,11,13,14,16-18,22,24,26,28,30,41,42,46,48)

For minitubular and endoscopic approaches, the clinical results of the present series are parallel to the literature review. However, the conventional approach in the present series had significantly higher rates of intraventricular hemorrhage ($p=0.018$), infection ($p=0.035$) and neurological deficit ($p=0.04$) than the literature review (Table III).

When the three approaches in our literature review were compared, the seizure rate was significantly higher in the conventional approach than the minitubular and endoscopic approaches ($p<0.001$). In terms of residue, the endoscopic approach had significantly higher rates of residual cyst compared to conventional and minitubular approaches ($p<0.001$). No statistically significant difference was found between the three approaches regarding permanent neurological deficit ($p=0.738$).

Table IV: Detailed Presentation of the Literature Series

Series	Conventional Approach				Minitubular Approach			Endoscopic Approach														
	Solaröglü	Kondziolka	Desai	Alnaghmoosh	Kehler	Baras	Cabbel	Gadol	Abernathy	Decq	Boogaarts	Longatti	Horn	Grondin	Wilson	Hoffman	Srbnick	Botella	Levine	Hellwig	Zohdi	Kehler
Total no patient	27	20	30	5	9	16	18	5	12	15	90	61	28	25	22	56	56	24	35	20	18	10
Mean age (years)	34.2	38		14.4	46.4	36	43	35	50.7	40.86	43	41	49	45.1	47	40.9	42.2	39.6	35.9	43	33.6	49.2
Range of age	12-61	14-65	10-68	6-18	32-61	17-62	16-68	26-54	25-71	22-76	16-77	9-78	35-63	15-74	22-72	9-69	16-77	15-73	14-58	16-64	14-60	27-75
Sum of the ages	923	760		72	418	576	774	175	609	613	3870	2501	1372	1127	1034	2334	2363	950	1256	860	605	492
Sex (M/F)	13/14	10/10	20/10	2/3	3/6	11/5	10/8		6/6	10/5	52/38	34/27	14/14	18/7	14/8	24/32	29/27	17/7	19/16	13/7	10/8	7/3
Hydrocephalus	27	14		5		15	13	3	12	14	72	53	17	22	19	37	33	24	31	19	18	10
Mean Cyst diameter				15		18		15		22.93	16.4	14.6	13	13.5	12	12.8	9.8	16.25	12.5			15
Sum of diameters				75		289		75		343	1476	890	364	337	264	742	549	390	438			
Range of diameters				10-25		8-23		10-22		4-50	7-50	6-32	8-18	5-23	6-22	5-34	3-23	10-35	5-40			
Length of incision (mm)				25		10		12	20													
Conversion to craniotomy										0	2	2	1	0	0	0	0	3	0			
Residual tumor						0	0	0	1	3	39	38	9	2	4	9	0	1		3		7
Shunt dependency						0	1	2	1	0	3	20	2	1	4	2	3	0	3	1		0
IVH						0	0	0	0	0	0	3	0	0	0	0	1	3	1	1	2	1
Infection						1	1	0	0	1	10	1	0	0	0	2	3	3	0	1	0	1
Postop Seizure						2	1	8	1	0	1	0	0	1	0	0	0	0	0	0	0	0
Permanent neurological deficit						0	0	1	1	2	1	2	3	1	1	0	6	3	5	2	0	0
Mortality						0	0	1	1	0	1	0	0	0	0	0	2	0	0	0	0	0
Mean FU period(mo)	41	51.6	44	47.2	42	42	10	19	15.26	51	32	10	38	14.3	40.4	14.9	67.2	93.6	64	50	19	
Range of FU	8-78	6-132	1-300	12-96	0-92	9-121	3-18	6-46	1-28	1-144	1-132	8-12	0-102	1-144	1-57	6-132	19-147	12-117	5-99	2-47		

M: Male, F: Female, IVH: Intraventricular hemorrhage, FU: Follow-up, mo: months.

■ DISCUSSION

The anatomical location of CC makes its total excision difficult. The ideal surgical approach for the removal of CC is controversial (10). Taking advantage of dilated ventricles caused by obstruction of the foramen of Monro, transcortical transventricular microsurgical approach was considered to be the best strategy for a long time, as this dilation of the ventricles facilitates surgical access. However, this approach required frontal cortex incisions and lobar dissections of considerable length (10,13). Postoperative CT examinations often showed extensive hypodensities related to parenchymal dissection and retraction. Such injuries, once considered an acceptable price in some cases, are now unacceptable (27).

The interhemispheric transcallosal approach was therefore designed and proposed in order to avoid this cortical infringement, as the corpus callosum is the only structure that needs to be sectioned to access the ventricle and the CC (37,44,47). Different types of memory impairment, motor coordination and attention deficits have been reported in up to 83% of patients with CC who were operated via the transcallosal approach (19,33). Another significant complication of this approach is venous infarction (43). The transcallosal interforaminal route also resulted in high rates of fornix injury (2,29).

Severe consequences of these approaches have led to the proposal of percutaneous techniques like stereotactic cyst aspiration without removal (10). Unfortunately recurrences were encountered in the short term (26,32). The microsurgical approach via stereotactically guided minitubular retractors was developed to increase the precision of the approach, thereby minimizing the injury to the brain parenchyma (4,6). No prominent side effects and morbidities are reported (1,4,6,8).

Another development was achieved via the neuroendoscope as it enables a "simple" percutaneous procedure like aspiration but at the same time carries the potential of performing cyst resection. Difficulties encountered in the early years, such as blurring of the field or inability to grasp and remove the cysts, have been overcome by the accumulation of experience and the development of better instruments. Dual-instrument applications from a single working channel resulted in total excision rates of 82% (46).

Cortical incisions may lead to epilepsy and the conventional transfrontal approach is known to result in high rates of seizures. Incisions up to 3 cm, and parenchymal dissections, which could be unduly extensive in the absence of guidance or navigation, resulted in seizure rates of up to 27% (13). Our literature review revealed an overall seizure rate of 13% for conventional surgery. The seizure rate in our 11 cases that underwent conventional surgery was 27% in which all the patients were seizure free after increasing doses of antiepileptic drugs. On the other hand, our seizure rates for minitubular or endoscopic resections were 0%. Our literature review showed seizure rates of 4% for minitubular approach and 0.5% for endoscopic series. This is highly significant: smaller incisions, less invasive approaches lead to significantly lower rates of seizure. Thus the rationale of

greater seizure rates for conventional approach compared to minitubular and endoscopic approaches can be attributed to longer cortical incision lengths. Furthermore, during the course of the conventional approach, retractor blades are used which may lead to cerebral infarction due to excessive force of retraction and accidental cutting of brain tissue (4). Furthermore, the retractor blade is generally used with a fixator that also increases the parenchymal damage due to continuous pulling force throughout the resection period. During the minitubular approach, there is no need for a fixator holding the lightweight cylindrical retractor since it stays suspended within the brain parenchyma immovably (4). The forces that create a parenchymal damage by retractor blade (conventional approach) versus cylindrical plastic retractor (minitubular approach) are different in magnitude. While the blade exerts disproportionate force in one direction, the cylindrical retractor distributes the forces equally over 360 degrees reducing the pressure considerably over unit area. The same argument is true for the endoscopic approach since the diameter of the endoscope (2.7 mm) is considerably smaller than the cylindrical retractor (14 mm) and no retractor blades are used.

The ideal treatment of CC must focus on total removal. A recent meta-analysis of 1278 CC patients (583 microsurgical, 695 endoscopic) showed that the microsurgical group has a higher gross total resection rate, lower recurrence rate and lower reoperation rate compared to endoscopic group (39). In the present series, residual tumors were detected in three patients; two in the endoscopic and one in the conventional approach group. When residual tumor rates of the present series and our literature review are compared, the rates are 22% vs. 28% in the endoscopic, 0% vs. 3% in the minitubular and 0% vs. 2% in the conventional approach, respectively. As a result, the present series showed comparable results with the literature in that endoscopic approaches for the removal of CC have higher residual tumor rates compared to microsurgical approaches. In the present series, there were more favorable residual tumor ratios of 0/11 (0%) in the conventional and 0/21 (0%) in the minitubular approaches against 2/9 (22%) in endoscopic approach ($p=0.024$). The high rate of incomplete removal for endoscopic CC surgery is attributed to the anatomical location of the cyst, which is tucked up underneath the roof of the third ventricle and difficult to reach through a burrhole located near the coronal suture with a rigid endoscope. Studies on the use of novel approaches to overcome this anatomical difficulty, or with dual endoscopic instruments report higher rates of total removal compared to standard endoscopic methods (7,22,46).

In the literature, most of the patients had symptoms of hydrocephalus on admission (39). Our literature review showed that 80% of endoscopically operated, 84% of minitubular approach and 75% of conventionally operated patients were hydrocephalic. In the present series, ventricular enlargement was present in all of the 41 patients except one (97%). However with liberal use of cranial radiological examinations, especially MRI, more patients are being diagnosed with CC in the absence of hydrocephalus. Optimal management of patients with CC and normal ventricles is unclear (45). Wait et al.

reported that normal size ventricles are not a contraindication to endoscopic removal of CC (45). On the other hand, many authors advocate a wait-and-see approach (15,41). In most patients, removal of the cyst leads to reduction in the ventricle size and resolution of hydrocephalus symptoms. In the present series, postoperative shunt dependency was independent of the type of surgical approach and this result was compatible with the literature (39).

Hemiparesis is a known but rare complication of CC surgery (38,39,43). Sampath et al. reported postoperative hemiparesis in a patient whose craniotomy was unintentionally localized near the motor cortex. They also stated that the endoscopic approach with a far frontal trajectory is very unlikely to be associated with this type of morbidity (38). This statement was true for the current series since none of the patients that were operated via endoscopic approach had hemiparesis postoperatively. Also, none of the patients who were operated via stereotactically guided minitubular approach had hemiparesis postoperatively. Two of our patients had permanent hemiparesis, both of whom had undergone a conventional approach that was statistically significant ($p < 0.05$). On the other hand, in their meta-analysis Sheikh et al. reported that hemiparesis was independent of the surgery type. They stated that the overall rate of hemiparesis was 0.9% in endoscopic vs. 1.9% in the transcortical microscopic series which was statistically insignificant (39).

The only mortality in this series was seen in the conventional approach group. Patient 11, who had been diagnosed with CC eight years ago and refused surgery, presented comatose and could not be saved despite urgent intervention. This mortality shows the potential fatality of CC and corroborates to the literature regarding the lethality of CC (34,40). Asymptomatic patients that were diagnosed with CC incidentally must be warned carefully against the possible forthcoming increased intracranial pressure (ICP) symptoms and fatality. In this series, more patients had presented with coma in the earlier years (Patient 12, 13, 14), whereas in the later periods the cardinal symptom had become headache. This situation is attributable to the ease of access to radiological imaging techniques in the later years.

Patients in the minitubular approach group had the best results in terms of completeness of removal, seizure rates and neurological deficit rates in both the present series and the literature review. This approach, unlike the other two, was stereotactically guided.

A major shortcoming of this report is its inability to include into its comparison the use of neuronavigation, which undoubtedly had a positive effect on the results. Studies performed on series using neuronavigation-assisted endoscopy and transfrontal microsurgery will be able to clarify this issue.

■ CONCLUSION

With respect to complication rates, stereotactic and endoscopic approaches are both safe and reliable compared to conventional microsurgical approach that has high rates of seizures and neurological deficit. Concerning completeness

of removal, both microsurgical approaches are by far superior to neuroendoscopy. Stereotactic microsurgical approaches compare favorably in both respects with endoscopic and conventional microsurgical approaches.

■ REFERENCES

1. Abernathy CD, Davis DH, Kelly PJ: Treatment of colloid cysts of the third ventricle by stereotaxic microsurgical laser craniotomy. *J Neurosurg* 70(4):525-529, 1989
2. Aggleton JP, Brown MW: Episodic memory, amnesia, and the hippocampal-anterior thalamic axis. *Behav Brain Sci* 22(3):425-444, 1999
3. Alnaghmoosh N, Alkhani A: Colloid cysts in children, a clinical and radiological study. *Childs Nerv Syst* 22(5):514-516, 2006
4. Barlas O, Karadereler S: Stereotactically guided microsurgical removal of colloid cysts. *Acta Neurochir (Wien)* 146(11):1199-1204, 2004
5. Boogaarts HD, Decq P, Grotenhuis JA, Le Guérinel C, Nseir R, Jarraya B, Djindjian M, Beems T: Long-term results of the neuroendoscopic management of colloid cysts of the third ventricle: A series of 90 cases. *Neurosurgery* 68(1):179-187, 2011
6. Cabbell KL, Ross DA: Stereotactic microsurgical craniotomy for the treatment of third ventricular colloid cysts. *Neurosurgery* 38(2):301-307, 1996
7. Chibbaro S, Champeaux C, Poczos P, Cardarelli M, Di Rocco F, Iaccarino C, Servadei F, Tigan L, Chaussemy D, George B, Froelich S, Kehrli P, Romano A: Anterior trans-frontal endoscopic management of colloid cyst: An effective, safe, and elegant way of treatment. Case series and technical note from a multicenter prospective study. *Neurosurg Rev* 37(2):235-241, 2014
8. Cohen-Gadol AA: Minitubular transcortical microsurgical approach for gross total resection of third ventricular colloid cysts: Technique and assessment. *World Neurosurg* 79(1):207.e7-10, 2013
9. de Witt Hamer PC, Verstegen MJ, De Haan RJ, Vandertop WP, Thomeer RT, Mooij JJ, van Furth WR: High risk of acute deterioration in patients harboring symptomatic colloid cysts of the third ventricle. *J Neurosurg* 96(6):1041-1045, 2002
10. Decq P: Endoscopy or microsurgery: Is the never-ending debate concerning the choice of surgical strategy for colloid cysts of the third ventricle still a topical issue or has it been resolved? *World Neurosurg* 80(5):498-499, 2013
11. Decq P, Le Guérinel C, Brugières P, Djindjian M, Silva D, Kéravel Y, Melon E, Nguyen JP: Endoscopic management of colloid cysts. *Neurosurgery* 42(6):1288-1294, 1998
12. Delitala A, Brunori A, Russo N: Supraorbital endoscopic approach to colloid cysts. *Neurosurgery* 69(2 Suppl Operative):ons176-182, 2011
13. Desai KI, Nadkarni TD, Muzumdar DP, Goel AH: Surgical management of colloid cyst of the third ventricle—a study of 105 cases. *Surg Neurol* 57(5):295-302, 2002
14. Grondin RT, Hader W, MacRae ME, Hamilton MG: Endoscopic versus microsurgical resection of third ventricle colloid cysts. *Can J Neurol Sci* 34(2):197-207, 2007
15. Grunert P, Hopf N, Perneczky A: Frame-based and frameless endoscopic procedures in the third ventricle. *Stereotact Funct Neurosurg* 68: 80-89, 1997

16. Hellwig D, Bauer BL, Schulte M, Gatscher S, Riegel T, Bertalanffy H: Neuroendoscopic treatment for colloid cysts of the third ventricle: The experience of a decade. *Neurosurgery* 52:525-533, 2003
17. Hoffman CE, Savage NJ, Souweidane MM: The significance of cyst remnants after endoscopic colloid cyst resection: A retrospective clinical case series. *Neurosurgery* 73(2):233-237, 2013
18. Horn EM, Feiz-Erfan I, Bristol RE, Lekovic GP, Goslar PW, Smith KA, Nakaji P, Spetzler RF: Treatment options for third ventricular colloid cysts: Comparison of open microsurgical versus endoscopic resection. *Neurosurgery* 60:613-618, 2007
19. Hütter BO, Spetzger U, Bertalanffy H, Gilsbach JM: Cognition and quality of life in patients after transcallosal microsurgery for midline tumors. *J Neurosurg Sci* 41(1):123-129, 1997
20. Hwang DH, Townsend JC, Ilsen PF, Bright DC: Colloid cyst of the third ventricle. *J Am Optom Assoc* 67(4): 227-234, 1996
21. Iacoangeli M, di Somma LG, Di Rienzo A, Alvaro L, Nasi D, Scerrati M: Combined endoscopic transforaminal-transchoroidal approach for the treatment of third ventricle colloid cysts. *J Neurosurg* 120(6):1471-1476, 2014
22. Ibáñez-Botella G, Domínguez M, Ros B, De Miguel L, Márquez B, Arráez MA: Endoscopic transchoroidal and transforaminal approaches for resection of third ventricular colloid cysts. *Neurosurg Rev* 37(2):227-234, 2014
23. Jeffree RL, Besser M: Colloid cyst of the third ventricle: A clinical review of 39 cases. *J Clin Neurosci* 8:328-331, 2001
24. Kehler U, Brunori A, Gliemroth J, Nowak G, Delitala A, Chiappetta F, Arnold H: Twenty colloid cysts-comparison of endoscopic and microsurgical management. *Minim Invasive Neurosurg* 44:121-127, 2001
25. Kelly PJ, Goerss SJ, Kall BA: The stereotaxic retractor in computer-assisted stereotaxic microsurgery. Technical note. *J Neurosurg* 69(2):301-306, 1988
26. Kondziolka D, Lunsford LD: Stereotactic management of colloid cysts: Factors predicting success. *J Neurosurg* 75(1):45-51, 1991
27. Lanzino G: Retractorless brain surgery. *J Neurosurg* 116(2):290, 2012
28. Levine NB, Miller MN, Crone KR: Endoscopic resection of colloid cysts: Indications, technique, and results during a 13-year period. *Minim Invasive Neurosurg* 50(6):313-317, 2007
29. Lewis AI, Crone KR, Taha J, van Loveren HR, Yeh HS, Tew JM Jr: Surgical resection of third ventricle colloid cysts. Preliminary results comparing transcallosal microsurgery with endoscopy. *J Neurosurg* 81:174-178, 1994
30. Longatti P, Godano U, Gangemi M, Delitala A, Morace E, Genitori L, Alafaci C, Benvenuti L, Brunori A, Cereda C, Cipri S, Fiorindi A, Giordano F, Mascari C, Oppido PA, Perin A, Tripodi M; Italian Neuroendoscopy Group: Cooperative study by the Italian neuroendoscopy group on the treatment of 61 colloid cysts. *Childs Nerv Syst* 22:1263-1267, 2006
31. Maeder PP, Holtas SI, Basibüyük LN, Salford LG, Tapper UA, Brun A: Colloid cysts of the third ventricle: Correlation of MR and CT findings with histology and chemical analysis. *AJNR* 11:575-581, 1990
32. Mathiesen T, Grane P, Lindquist C, von Holst H: High recurrence rate following aspiration of colloid cysts in the third ventricle. *J Neurosurg* 78(5):748-752, 1993
33. McMackin D, Cockburn J, Anslow P, Gaffan D: Correlation of fornix damage with memory impairment in six cases of colloid cyst removal. *Acta Neurochir (Wien)* 135(1-2):12-18, 1995
34. Opeskin K, Anderson RM, Lee KA: Colloid cyst of the 3rd ventricle as a cause of acute neurological deterioration and sudden death. *J Paediatr Child Health* 29(6):476-477, 1993
35. Parwani AV, Fatani IY, Burger PC, Erozan YS, Ali SZ: Colloid cyst of the third ventricle: Cytomorphologic features on stereotactic fine-needle aspiration. *Diagn Cytopathol* 27(1):27-31, 2002
36. Patel N, Rao VA, Heilman-Espinoza ER, Lai R, Quesada RA, Flint AC: Simple and reliable determination of the modified Rankin Scale in neurosurgical and neurological patients: The mRS-9Q. *Neurosurgery* 71(5): 971-975, 2012
37. Petrucci RJ, Buchheit WA, Woodruff GC, Karian JM, DeFilipp GJ: Transcallosal paraforaminal approach for third ventricle tumors: Neuropsychological consequences. *Neurosurgery* 20(3):457-464, 1987
38. Sampath R, Vannemreddy P, Nanda A: Microsurgical excision of colloid cyst with favorable cognitive outcomes and short operative time and hospital stay: Operative techniques and analyses of outcomes with review of previous studies. *Neurosurgery* 66(2):368-374, 2010
39. Sheikh AB, Mendelson ZS, Liu JK: Endoscopic versus microsurgical resection of colloid cysts: A systematic review and meta-analysis of 1,278 patients. *World Neurosurg* 82(6):1187-1197, 2014
40. Shemie S, Jay V, Rutka J, Armstrong D: Acute obstructive hydrocephalus and sudden death in children. *Ann Emerg Med* 29(4):524-528, 1997
41. Solaroglu I, Beskonakli E, Kaptanoglu E, Okutan O, Ak F, Taskin Y: Transcortical-transventricular approach in colloid cysts of the third ventricle: Surgical experience with 26 cases. *Neurosurg Rev* 27(2):89-92, 2004
42. Sribnick EA, Dadashev VY, Miller BA, Hawkins S, Hadjipanayis CG: Neuroendoscopic colloid cyst resection: A case cohort with follow-up and patient satisfaction. *World Neurosurg* 81(3-4):584-593, 2014
43. Symss NP, Ramamurthi R, Kapu R, Rao SM, Vasudevan MC, Pande A, Cugati G: Complication avoidance in transcallosal transforaminal approach to colloid cysts of the anterior third ventricle: An analysis of 80 cases. *Asian J Neurosurg* 9(2):51-57, 2014
44. Timurkaynak E, Izci Y, Acar F: Transcavum septum pellucidum interforniceal approach for the colloid cyst of the third ventricle. *Operative nuance. Surg Neurol* 66(5):544-547, 2006
45. Wait SD, Gazzeri R, Wilson DA, Abla AA, Nakaji P, Teo C: Endoscopic colloid cyst resection in the absence of ventriculomegaly. *Neurosurgery* 73(1 Suppl Operative):39-47, 2013
46. Wilson DA, Fusco DJ, Wait SD, Nakaji P: Endoscopic resection of colloid cysts: Use of a dual-instrument technique and an anterolateral approach. *World Neurosurg* 80(5):576-583, 2013
47. Winkler PA, Weis S, Wenger E, Herzog C, Dahl A, Reulen HJ: Transcallosal approach to the third ventricle: Normative morphometric data based on magnetic resonance imaging scans, with special reference to the fornix and forniceal insertion. *Neurosurgery* 45(2):309-319, 1999
48. Zohdi A, El Khashin S: Endoscopic approach to colloid cysts. *Minim Invasive Neurosurg* 49(5):263-268, 2006