



DOI: 10.5137/1019-5149.JTN.17111-16.2

Received: 08.02.2016 / Accepted: 05.05.2016

Published Online: 08.08.2016

Case Report

Whipple Disease Presenting as Cystic Brain Tumor: Case Report and Review of the Literature

Mohamed KILANI¹, Leila NJIM², Atef Ben NSIR¹, Mohamed Nejib HATTAB¹

¹Fattouma Bourguiba University Hospital, Department of Neurosurgery, Monastir, Tunisia

²Fattouma Bourguiba University Hospital, Department of Pathology, Monastir, Tunisia

ABSTRACT

Although neurological features are commonly encountered in Whipple's disease (WD), presentation with purely neurological patterns is uncommon. Exclusive confinement to the central nervous system (CNS) is extremely rare. In these cases, the development of an isolated cerebral mass is exceptional.

In the present paper, the authors describe a case of a 68-year-old man who presented with partial seizures. The neurological examination was normal. The imaging showed a cystic lesion. This tumor-like lesion was removed by performing frontal craniotomy. A histopathological investigation revealed the presence of numerous perivascular foamy histiocytes infiltrating the brain parenchyma. The majority of these histiocytes showed Periodic acid-schiff (PAS)-positive intense staining, which is distinctive feature of cerebral WD. The diagnosis was confirmed by polymerase chain reaction (PCR) analysis of cerebrospinal fluid. There were no gastrointestinal symptoms and no PAS inclusions in intestinal mucosa. The patient received Ceftriaxone intravenously followed by oral trimethoprim-sulfamethoxazole (TMP-SMZ) for 12 months and recovered well. This case illustrates atypical WD, confined exclusively to the central nervous system.

KEYWORDS: Whipple disease, *Tropheryma whippelii*, Encephalitis, Central nervous system

INTRODUCTION

Whipple's disease (WD) is a rare multisystem infectious disease caused by a slow growing soil-borne Gram-positive bacillus *Tropheryma whippelii* (*T. whippelii*), related to the family of actinomyces. Humans are the only known host for the infection (9). This chronic infection is characterized by predominant intestinal involvement. Weight loss, diarrhea, low-grade fever and arthralgia have all been recorded to be major symptoms of WD (11).

The central nervous system (CNS) may be involved around 10-43% in patients with multisystem WD. The neurological manifestations are diverse and can mimic almost any neurological condition (10). These manifestations occur in three circumstances: CNS relapse of previously treated classic WD, neurological involvement in untreated classic WD, and isolated neurological symptoms due to *T. whippelii* (3).

We present the first case of isolated cerebral Whipple's disease presenting as a binocular cyst.

CASE REPORT

A 68-year-old right handed man was referred to our institution after suffering two simple partial epileptic seizures localized in the left side of his body. He had experienced problems of concentration and increasing irritability for a month without any headache. There was no history of fever, weight loss or recurring episodes of arthralgia.

On admission, the patient was afebrile and all vital signs were normal. The results of a neurological examination were normal. The digestive system and joints were normal.

Magnetic resonance imaging (MRI) revealed a right frontal binocular cyst in the subcortical white matter. The lesion was



Corresponding author: Mohamed KILANI

E-mail: kilanineurochirurgien@gmail.com

hypo-intense on T1-weighted images and hyper-intense on T2-weighted images. Transient contrast enhancement was noticed after injection of contrast agent (Figure 1A, B). There was a marked edema surrounding the lesion. The midline structures were shifted to the left side. The lesion was thought to be a glioblastoma or a hydatid cyst.

The lesion was removed by a right frontal craniotomy. At surgery, the lesion appeared macroscopically like an old hematoma. There was a fragile and thin membrane separating two cysts. The tumor-like tissue could hardly be differentiated from surrounding brain. The lesion vessels were vulnerable. The removal was estimated to be complete macroscopically.

The neuropathological examination revealed reactive gliosis and infiltration of the brain parenchyma by a large number

of perivascular foamy histiocytes. Periodic Acid-Schiff (PAS) preparation revealed intense staining in the macrophages and histiocytes which is a characteristic findings of cerebral WD (Figure 2A, B). Special staining for acid-fast bacilli and fungi were negative. There was no evidence of tumor.

The patient was placed on anti-epileptic medication on admission. Upper intestinal endoscopy with duodenal and jejunal biopsies was performed. Histological examination of the specimens showed mostly normal tissue. Polymerase chain reaction (PCR) assay targeting the 16S rRNA gene of *T. whipplei* showed a positive result in the cerebrospinal fluid (CSF).

Antibiotic therapy with ceftriaxone (2g/day intravenously) was given for 2 weeks followed by TMP-SMZ (160/800

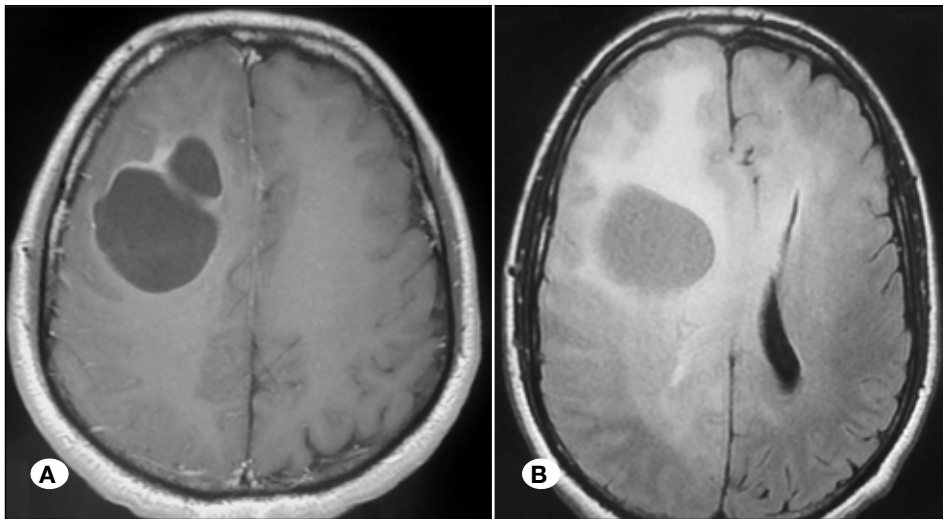


Figure 1: Axial T1-weighted brain MRI with gadolinium demonstrating transient enhancing binocular cyst in the right frontal lobe (A). FLAIR sequence showing edema surrounding the lesion and midline structures shifted to the left side (B).

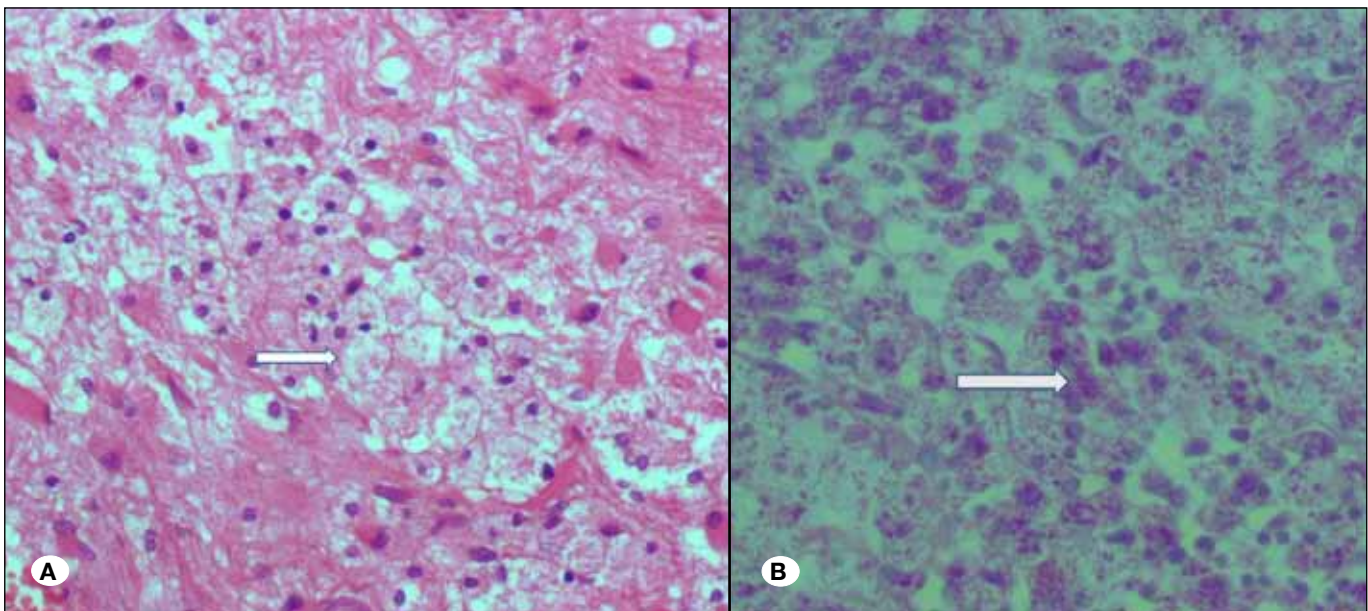


Figure 2: Histological section shows an expansion of the brain tissue by foamy macrophages (arrow); H&E, original magnification×200 (A). PAS stain reveals brightly staining granular intracytoplasmic inclusions (arrow); original magnification×200 (B).

mg twice a day) for 12 months. His concentration trouble gradually improved. At regular follow-up, the neurological examination remained stable. The patient had not developed any gastrointestinal symptoms. Follow-up MRI investigation performed 6 months after surgery showed no recurrence, but a persisting pseudocyst defect (Figure 3). Currently, the patient is seizure free. He continues to take TMP-SMZ on a regular basis.

■ DISCUSSION

Whipple's disease was first described in 1907 by George Whipple at Johns Hopkins (16). At present, we recognize *Tropheryma whipplei* as the causative agent of WD. In fact, Relman et al.(13) identified the bacterium as a Gram-positive actinomycete. Whipple's disease typically involves multiple organ systems (10,11). The symptoms of cerebral WD include oculomotor abnormalities, ataxia, seizures, psychiatric disturbances, dementia, and aseptic meningitis (2). These neurological symptoms are varied and often complex but oculomasticatory myorhythmia (OMM) and oculo-facial-skeletal myorhythmia (OFSM) are considered to be pathognomonic of CNS WD (10). Cases of WD with isolated involvement of the brain without any systemic affection appear to be rare. So far, only 21 cases have been reported in the literature (15).

The first question raised by the present report deals with the hypothesis of isolated CNS WD. Pruss et al. (12) suggest that the robust activity of duodenal lymphocytes may prevent bowel disease. On the contrary, the concomitant impaired activity of peripheral blood lymphocytes may lead to the bacterial

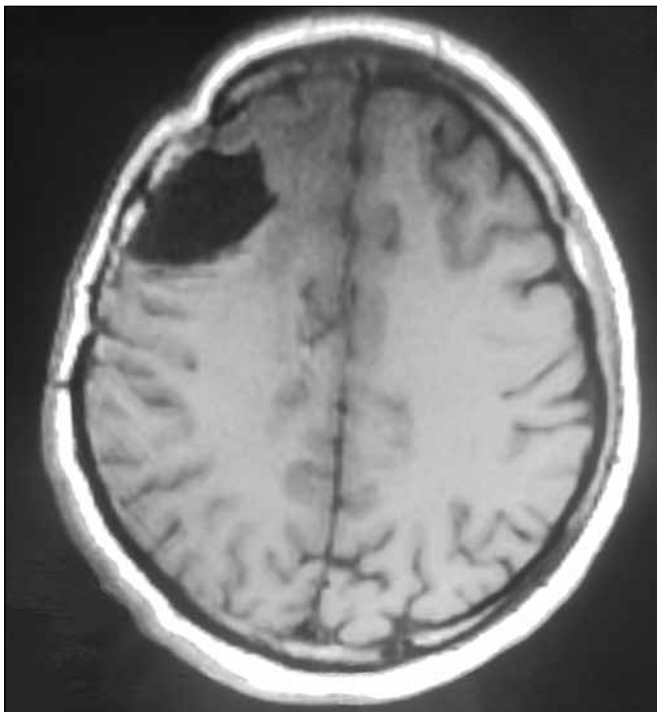


Figure 3: Follow-up T1-weighted brain MRI obtained 6 months after surgery revealed complete resolution of the lesion with a persisting pseudocyst defect.

spread to the CNS and cause neurological symptoms without systemic involvement.

CNS Whipple's disease presenting as a solitary mass is rather exceptional. Only 4 cases were reported (1,4,6,8). Among these, only 2 cases showed no systemic symptoms of Whipple's disease (Table I).

De Coen et al. (4) reported a case of a 49-year-old female who suffered from dysarthria, right facial palsy and hemiparesis. MRI showed the lesion to be hypointense on T1-weighted images with ring enhancement. It was thought to be a glioblastoma or a metastasis. Microscopic examination showed the presence of foamy macrophages with granules PAS positive. The patient was treated with trimethoprim. Follow-up MRI images showed complete resolution of the lesion.

Löhr et al. (8) report a case of a 40-year-old male suffering from bifrontal headache, speech disturbances and problems of concentration. The lesion was hypo-intense on T1-weighted images with circular contrast enhancement. It was thought to be a low-grade glioma. The patient was operated. The histopathological investigation showed pathological features of CNS WD. The patient received co-trimoxazole for one year post-operatively and remained symptom free.

As shown in these cases, brain MRI for diagnosis of CNS Whipple's disease is paramount, but nonspecific as with most infectious processes affecting the CNS (14). Herein we report the first case of CNS WD, consisting of binocular cyst. When consisting of solitary mass, WD gives rise to many differential diagnoses such as low-grade glioma, aggressive meningioma, metastasis (1,4,8), glioblastoma and even a hydatid cyst. Craniotomy and excision of the intracranial lesion leads to the diagnosis, when CNS WD is presenting as a solitary lesion (1,4,8). It is worth mentioning that, as in our case, when the lesion seems to be macroscopically different from the imaging diagnosis, WD should be suspected. In these four cases, the diagnosis was established by a histopathological analysis. It consists of an inflammatory reaction combining gliosis and vasculitis replacing normal cortex and white matter. Characteristic foamy macrophages are often seen, and their presence should heighten the clinical suspicion of WD. These macrophages stain very intensely with PAS stain (5). PCR analysis performed to detect 16S ribosomal RNA of *T. whipplei* is useful for both establishment of the diagnosis and monitoring the treatment response (13).

Early treatment of WD leads to improvement of the lesion (1,4,8) as shown in our case. Since CNS relapses carry a poor prognosis, antibiotics should not be reduced or discounted. They should be prescribed at least for one year to prevent relapses (7).

■ CONCLUSION

Isolated cerebral Whipple's disease often poses a great diagnosis challenge since its symptoms and neuroimaging signs are not specific. Although this disease usually presents as diffuse lesions, this report demonstrates that it can manifest as a solitary tumor-like lesion. This diagnosis should

Table 1: Review of the Literature of CNS Whipple's Disease Presenting as an Intracranial Mass

Year/ Author	Age/ Gender	Presentation	Imaging	Operation	CSF	Neural tissue	Extraneural tissue
1996/ (4)	49/F	Dysarthria, right facial palsy, right hemiparesis	Left parietal lesion T1: hypointense T2: hyperintense Ring enhancement	Tumor resection	Normal	FM PAS PG	Duodenal : negative
2002/(1)	18/M	Diarrhea, headache, partial epileptic seizures, left hemiparesis.	Right frontoparietal solid mass T1: isointense T2: hypointense Intense homogeneous enhancement Erosion of the tabula interna	Tumor resection	Normal	FM PAS PG LM : Positive	ND
2004/(8)	40/M	Headache, speech disturbance, irritability, aggressiveness	Left frontal mass T1: hypointense T2: hyperintense Ring enhancement	Tumor resection	Normal PCR: non diagnostic	FM PAS PG	Duodenal/ jejunal: negative
2009/ (6)	51/M	History of Whipple disease, headache, emesis, transient episodes of confusion.	Right temporal lobe, hypothalamus and left temporomesial lesions T1 with Gado: intense contrast enhancement T2: hyperintense	Temporal tumor resection	ND	FM PAS PG	ND
Present case	68/M	Partial epileptic seizures, problems of concentration, irritability	Right, frontal lesion T1: hypointense T2: hyperintense Transient contrast enhancement	Tumor resection	Normal PCR: positive	FM PAS PG	Duodenal/ jejunal: negative

ND: Not done, **FM:** foamy macrophages, **PAS PG:** PAS-positive granules, **LM:** light microscopy, **CSF:** cerebrospinal fluid.

be suspected when no tumor tissue is found at surgery. The excision or biopsy of the mass leads to the diagnosis. This should be kept in mind since the CNS WD is treatable if promptly diagnosed.

■ REFERENCES

1. Akar Z, Tanriover N, Tuzgen S, Canbaz B, Erman H, Oz B, Kuday C: Intracerebral Whipple disease: Unusual location and bone destruction: Case report. *J Neurosurg* 97:988-991, 2002
2. Anderson M: Neurology of Whipple's disease. *J Neurol Neurosurg Psychiatry* 68: 2-5, 2000
3. Compain C, Sacre K, Puéchal X, Klein I, Vital-Durand D, Houeto JL, De Broucker T, Raoult D, Papo T: Central nervous system involvement in Whipple disease: clinical study of 18 patients and long-term follow-up. *Medicine (Baltimore)* 92: 324-330, 2013
4. De Coene B, Gilliard C, Indekeu P, Duprez T, Trigaux JP: Whipple's disease confined to the central nervous system. *Neuroradiology* 38: 325-327, 1996
5. Durand DV, Lecomte C, Cathébras P, Rousset H, Godeau P: Whipple disease: Clinical review of 52 cases. *Medicine (Baltimore)* 76:170-184, 1997
6. Frazier JL, Quinones-Hinojosa A: Isolated Whipple disease of the brain resembling a tumour. *Acta Neurochir (Wien)* 151:173-175, 2009
7. Gerard A, Sarrot-Reynauld F, Liozon E, Cathébras P, Besson G, Robin C, Vighetto A, Mosnier JF, Durieu I, Vital Durand D, Rousset H: Neurologic presentation of Whipple disease: Report of 12 cases and review of the literature. *Medicine (Baltimore)* 81: 443-457, 2002
8. Löhr M, Stenzel W, Plum G, Gross WP, Deckert M, Klug N: Whipple disease confined to the central nervous system presenting as a solitary frontal tumor: Case report. *J Neurosurg* 101:336-339, 2004
9. Louis ED: Whipple's disease. *Curr Neurol Neurosci Rep* 3: 470-475, 2003
10. Louis ED, Lynch T, Kaufmann P, Fahn S, Odel J: Diagnostic guidelines in central nervous system Whipple's disease. *Ann Neurol* 40: 561-568, 1996
11. Marth T, Schneider T: Whipple disease. *Curr Opin Gastroenterol* 24: 141-148, 2008
12. Pruss H, Katchanov J, Zschenderlein R, Loddenkemper C, Schneider T, Moos V: A patient with cerebral Whipple disease with gastric involvement but no gastrointestinal symptoms: A consequence of local protective immunity? *J Neurol Neurosurg Psychiatry* 78: 896-898, 2006
13. Relman DA, Schmidt TM, MacDermott RP, Falkow S: Identification of the uncultured bacillus of Whipple's disease. *N Engl J Med* 327: 293-301, 1992
14. Scholz KB, Henning S, Paulus W, Knauth M: MRI finding in isolated cerebral manifestation of Whipple's disease: Case report and review of the literature. *Eur J Radiol* 59: 1-5, 2006
15. Sung VW, Lyerly MJ, Fallon KB, Bashir K: Isolated CNS Whipple disease with normal brain MRI and false-positive CSF 14-3-3 protein: A case report and review of the literature. *Brain Behav* 2: 838-843, 2012
16. Whipple GH: A hiterto undescribed disease characterized anatomically by deposits of fat and fatty acids in the intestinal and mesenteric lymphatic tissues. *John Hopkins Med Bull* 231: 283-287, 1907