



DOI: 10.5137/1019-5149.JTN.17105-16.0

Received: 24.01.2016 / Accepted: 13.04.2016

Published Online: 08.08.2016

Original Investigation

Does Right-Sided Language Lateralization on BOLD-fMRI Affect Postoperative Language Outcome for AVM Patients?

Zhi LIU^{1,2}, Xiaofeng DENG¹, Yong CAO¹, Yuanli ZHAO¹, Jizong ZHAO¹, Shuo WANG¹

¹Department of Neurosurgery, Beijing Tiantan Hospital, Capital Medical University; China National Clinical Research Center for Neurological Diseases (NCRC-ND); Center of Stroke, Beijing Institute for Brain Disorders; Beijing Key Laboratory of Translational Medicine for Cerebrovascular Disease, Beijing, China

²ChinaMeitan General Hospital, Department of Neurosurgery, Beijing, China

ABSTRACT

AIM: For cerebral arteriovenous malformations (AVMs) involving language areas, right-sided language lateralization on functional magnetic resonance imaging (fMRI) has been reported, which is regarded as language cortex reorganization. The authors attempted to study if this right-sided language lateralization affects postoperative language outcome.

MATERIAL and METHODS: Clinical and imaging data of 43 right-handed AVM patients who underwent preoperative fMRI were retrospectively reviewed. All lesions involved the language cortex, with the Broca area involved in 13 patients and the Wernicke area involved in 30 patients. Lateralization indices (LI) of BOLD signal activations were calculated to determine language lateralization. All patients underwent craniotomy and total resection. Western aphasia battery (WAB) was used to evaluate language functions preoperatively, 1-2 weeks after surgery and 6-30 months after surgery.

RESULTS: On preoperative fMRI, right-sided lateralization was observed in 18 patients (41.9%, R Group), including 3 with right-sided lateralization in the Broca area alone, 14 in the Wernicke area alone, and 1 in both areas. The other 25 patients were non-right-sided lateralized (NR Group). One week after surgery, 7 patients in the R Group (38.9%) and 11 patients in the NR Group (44.0%) had language function deterioration, and no significant difference was found ($p=0.983$). At long-term follow-up, 3 patients in the R Group (16.7%) and 4 patients in the NR Group (16.0%) still had aphasia, and no significant difference was observed ($p=1.000$).

CONCLUSION: Although right-sided lateralization on fMRI might suggest language cortex reorganization, it is not a factor predicting better postoperative language outcome for AVM patients.

KEYWORDS: Cerebral arteriovenous malformation, Language cortex reorganization, Functional magnetic resonance imaging, Aphasia

INTRODUCTION

Cerebral arteriovenous malformations (AVMs) are congenital vascular lesions. The pathological characteristics are direct communication of arteries to abnormal veins without interposing capillaries (7, 20). An interesting clinical phenomenon is that although AVMs may grow in the language cortex, they usually do not present with aphasia unless ruptured, as reported in our previous study, which

focused on the preoperative blood oxygen level-dependent (BOLD) functional magnetic resonance imaging (fMRI) of AVM patients (9). Our previous study also showed that for cerebral AVMs involving language areas at traditional anatomical locations, right-sided lateralization of BOLD signals is not rare (36.5%) (9). Both of these phenomena are considered as language cortex reorganization (1, 9).



Corresponding author: Shuo WANG

E-mail: captain9858@vip.sina.com

In our opinion, a better language outcome after AVM resection surgery might be expected for patients with right-sided lateralization of BOLD signals, because the language areas are thought to have transferred to the homologous regions of the right hemisphere and language function will therefore be seldom impaired by the surgery.

In this study, we retrospectively reviewed clinical and imaging data of 43 right-handed cerebral AVM patients who underwent BOLD fMRI studies, with all lesions located in the left hemisphere and involved language areas. Total resection under neuronavigation was performed on all patients. Language functions were evaluated preoperatively and postoperatively with the Western Aphasia Battery (WAB). The focus of this study was to demonstrate if right-sided language lateralization on preoperative fMRI affects postoperative language outcome.

■ MATERIAL and METHODS

Patient Demographics

This study was approved by the Institutional Review Board (IRB) of Beijing Tiantan hospital, Capital Medical University, and all participating patients gave consent. We retrospectively reviewed the medical records and imaging studies of 43 cerebral AVMs patients, who underwent fMRI for preoperative evaluation between January 2013 and April 2015. Selection criteria were as follows: 1. all patients were right-handed, demonstrated by the Edinburgh handedness inventory (8); 2. all lesions were located in the left hemisphere and involved the language cortex, including the Broca (inferior frontal and middle frontal gyri, including Brodmann area 44, 45, 9, 46) and Wernicke (supramarginal, angular, and superior temporal gyri, including Brodmann area 22, 21, 39, 40) areas (5); 3. patients underwent surgical resection under neuronavigation. None of these patients were included in our previous study (9).

According to the criteria, as shown in Table I, 43 patients were enrolled in this study, including 31 males and 12 females. Ages ranged from 11 to 55 years with an average of 29.9 ± 12.5 years. Main clinical presentations included hemorrhage in 17 patients (39.5%), seizures in 15 (34.9%), headache in 6 (20.0%), dizziness in 3 (7.0%), aphasia in 1 (2.3%), and asymptomatic in 1 patient (2.3%). Two patients had undergone stereotactic radiosurgery (SRS) and 1 patient endovascular embolization. Thirteen patients' lesions involved the Broca area, and the other 30 patients' lesions involved the Wernicke area. The mean diameter of the AVMs was 41.4 mm (range, 9.8-82.9 mm). According to Spetzler-Martin (S-M) grading system, there were 7 grade II patients, 30 grade III patients and 6 grade IV patients (7, 20).

fMRI Acquisition

A Siemens Medical Systems Trio 3.0 T MRI system equipped at the 306th hospital of People's Liberation Army was used for fMRI signal acquisition, which was performed approximately 1-2 weeks before surgery. Every patient underwent a localizing image scan followed by a T2 structure image scan; then a T2-weighted functional image was obtained (T2-weighted

gradient echo, echo-planar imaging, TR = 3000 ms, TE = 30 ms, FOV = 220 × 220 mm², flip angle = 9°, matrix = 64 × 64, slice thickness = 1.0 mm, voxel size = 1.0 × 1.0 × 1.0 mm³); finally, a T1-weighted three-dimensional fine structure image was scanned (TR = 2300 ms, TE = 2.98 ms, flip angle = 9°, FOV = 256 × 256 mm², matrix = 64 × 64, slice thickness = 1.0 mm, voxel size = 1.0 × 1.0 × 1.0 mm³).

Informed consent complying with local IRB regulations was obtained from all patients. Block-designed fMRI was performed and patients were tested with two lexical-semantic language paradigms: picture naming and verb generation. During picture naming, different pictures were visually presented to the center of the patient's visual field. The patient was instructed to silently name each object as it appeared. In the control condition, the patient was instructed to passively view a picture of chopsticks. During verb generation, common concrete (written) nouns were presented to the center of the patient's visual field. The patient was instructed to silently generate a verb associated with each noun. In the control condition, the patient passively viewed a pound sign (#). During each paradigm, a set of 40 tasks was divided equally into 8 performance periods of 5 tasks each and interleaved with 8 control condition periods. Tasks were presented at a rate of one every 3 seconds. Before scanning, all patients were trained with the paradigms using stimuli different from those presented during the imaging protocol, and all of them demonstrated the ability to perform the tasks.

Image Processing

fMRI data was processed on a Matlab 8.4 workstation (Mathworks, Natick, Massachusetts) with SPM 8 (London University) and xjView toolbox (Stanford University). Voxels that exceeded a predetermined significance threshold ($p < 0.001$) were overlaid on the T1-weighted structure images to display the anatomical location of brain activity (9).

The method determining language lateralization was concordant with our previous study (9). Language lateralization was studied in the Broca and Wernicke areas separately (24). The Broca area refers to the inferior frontal and middle frontal gyri, including Brodmann area 44, 45, 9, 46. The Wernicke area is defined as the supramarginal, angular, and superior temporal gyri, including Brodmann area 22, 21, 39, 40. The lateralization index (LI) was used to quantify the degree of lateralization of BOLD signal activations: $LI = (VL - VR) / (VL + VR)$, where VL denotes the number of voxels activated in the left hemisphere and VR is the number of voxels activated in the right hemisphere. Language activation was categorized into 3 patterns. An LI less than or equal to -0.2 was defined as right-sided lateralization of BOLD signal activations (R Group), whereas an LI greater than or equal to 0.2 was considered as left-sided lateralization. An LI between -0.2 and 0.2 was regarded as no clear hemispheric preference (17). In this study, patients with left-sided lateralization or no clear hemispheric preference were both categorized in the non-right group (NR Group).

Treatment

fMRI data was further processed on a Brainlab workstation and used for intraoperative neuronavigation. All the 43 AVM

patients were surgically treated and total resection was achieved in all patients, which was confirmed by postoperative digital subtraction angiography (DSA). No patient underwent Wada test or intraoperative electrocortical stimulation mapping (ESM) (3, 27).

Language Function Evaluation and Follow-up

Language function was evaluated with WAB before surgery, at short-term follow-up (1-2 weeks after surgery), and at long-term follow-up (6-30 months after surgery) (10).

Statistical Analysis

All statistical analyses were performed with SPSS (Windows version 18.0, IBM). Chi-square test for the RxC contingency tables was used to analyze the difference of language

dysfunction between groups. A probability value <0.05 was considered as statistically significant.

RESULTS

Clinical and Imaging Characteristics

Twelve males and 6 females, with ages ranging from 20 to 55 years (mean 29.9 ± 12.5 years) were enrolled in the R Group. Four patients had lesions involving the Broca area (Figure 1A-F) and 14 patients had lesions involving the Wernicke area (Figure 2A-F). Lesion size ranged from 19.5 to 66.1 mm (mean 39.1 ± 11.8 mm). There were 3 S-M grade II patients, 14 grade III patients, and 1 grade IV patient.

Meanwhile, 19 males and 6 females, with ages ranging from 11 to 53 years (mean 26.5 ± 12.6 years) were enrolled in the NR Group. Nine patients had lesions involving the Broca area and 16 patients had lesions involving the Wernicke area. The average lesion size was 43.1 ± 18.3 mm (range, 9.8-82.9 mm). There were 4 grade II patients, 16 grade III patients, and 5 grade IV patients.

Statistical results showed that there was no significant difference between the two groups in gender ($\chi^2: 0.453$, $p=0.501$), age ($p=0.926$, by independent t-test), lesion location ($\chi^2: 0.942$, $p=0.332$), lesion size ($p=0.062$, by independent t test) or S-M grades ($p=0.386$, by Mann-Whitney test).

fMRI data analysis

According to the above-mentioned criteria, as shown in Table I, right-sided lateralization was observed in 18 patients (41.9%, R Group), including 3 with right-sided lateralization in the Broca area alone, 14 in the Wernicke area alone, and 1 in both areas. The other 25 patients were non-right-sided lateralized (NR Group), including 22 patients with left-sided lateralization and 3 patients with no clear hemispheric preference.

Language Function Evaluation and Follow-up

Postoperatively, all patients were followed up. The follow-up duration ranged from 6 to 30 months, with an average period of 18 months. The language functions according to the WAB tests were summarized in Table I.

Preoperative Evaluation

Before surgery, 2 patients presented with anomic aphasia after intracranial hemorrhage (cases 7 and 29). The other patients' language functions were normal. Although the initial presentation of case 6 was transient aphasia, his language function recovered to normal at admission.

Short-term Outcome (1-2 weeks after surgery)

In the R Group, 11 patients maintained their language status (61.1%), including case 7, who had anomic aphasia both before and after surgery. Seven patients' (38.9%) language function deteriorated in the short-term postoperative period, including 6 patients with anomic aphasia, 1 with motor aphasia, and 1 with conduction aphasia. In the NR Group, 14 patients' language status was stable (56.0%), including case 29, who had anomic aphasia both before and after surgery.

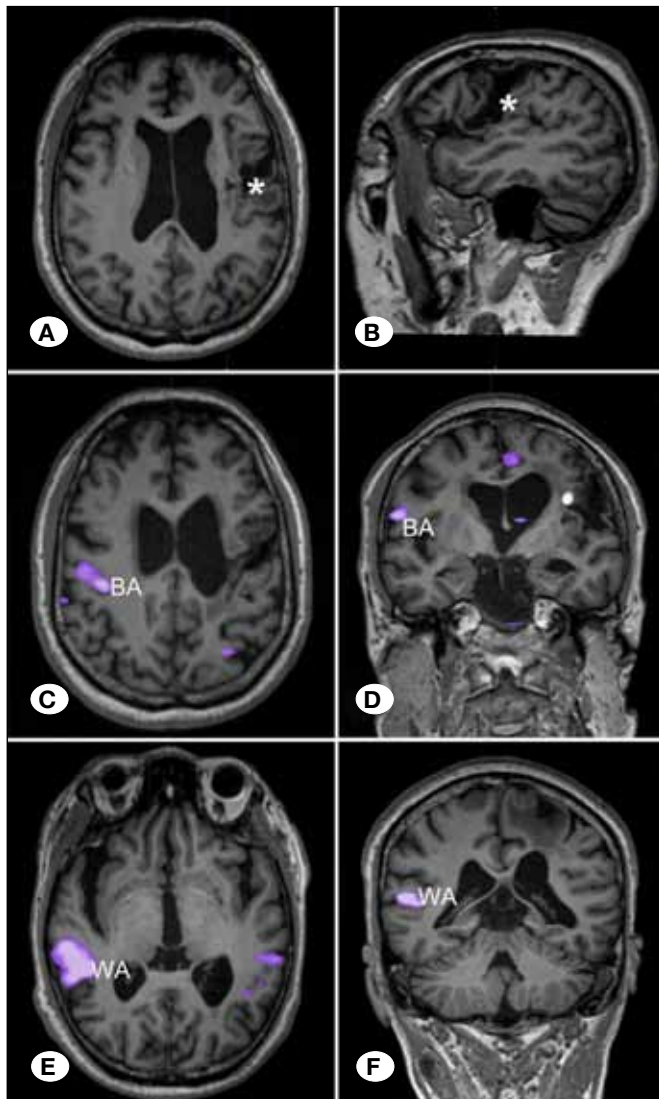


Figure 1: MRI of a patient in R Group, with lesions involving the Broca area (case 4). T1-weighted sagittal (A) and axial (B) MR images revealed an AVM (*) involving the Broca area. fMRI images showed right-sided lateralization of both the Broca (C, D "BA") and Wernicke (E, F "WA") areas.

Language function deterioration was observed in 11 patients (44.0%), including 6 patients with anomic aphasia, 4 with conduction aphasia, and 1 with transcortical motor aphasia. Although the incidence of language function deterioration was higher in the NR Group (44.0%) than in the R Group (38.9%), no significant difference was observed ($c2: 0.112, p=0.738$).

Long-term Outcome (6-30 months after surgery, the most recent follow-up)

As shown in Table I, in the R Group, 3 patients (16.7%) still had aphasia (including 2 with conduction aphasia and 1 with anomic aphasia), and the other 5 patients restored their language function. In the NR Group, 4 patients (16.0%) still had aphasia (including 3 with anomic aphasia and 1 with conduction aphasia), the other 8 patients' language functions returned to normal. Likewise, no significant difference of aphasia was observed between the R Group and the NR Group ($c2: 0.000, p=1.000$).

DISCUSSION

Left Hemisphere Language Dominance and Its Challenge

One major question in neuroscience is how each hemisphere contributes to language processing, as the most confusing morphological characteristic of the human brain is that the two cerebral hemispheres are seemingly symmetrical. The left hemisphere language dominance for right-handed human was recognized at the end of the 19th century. A patient who had lost the ability to speak was referred to a French surgeon Paul Broca. After autopsy, Broca found a lesion in the left inferior frontal gyrus (IFG) and associated this region with the capacity for articulate speech (13). In addition, supported by Wernicke's association of the sound of words with the left posterior superior temporal gyrus (STG) and Dejerine's recognition of the acquired inability to read and write following left angular gyrus damage, a dominant role of the left hemisphere in language processing for right-handed human was established (4, 19).

The neurological axiom of exclusive left hemisphere dominance in language was fundamentally challenged by behavioral studies with callosotomy patients. In the "split-brain" syndrome, unilateral sensory input is transmitted to the contralateral hemisphere, where, due to the lack of interhemispheric connections, it cannot be shared with the opposite hemisphere. For example, language stimuli transmitted to the right hemisphere were not available for processing in the left hemisphere. Therefore, the role of the right hemisphere in language has been gradually recognized, no matter in healthy population or in aphasia patients (12, 26).

Modalities for Assessment of Language Dominance

Clinically, there are several techniques for judging language dominance and language mapping, including intra-arterial Amytal injection (Wada test), ESM, fMRI, Magnetoencephalography (MEG), and radionuclide scanning (SPECT and PET). The Wada test has conventionally been recognized as the gold standard for assessment of language dominance. It is, however, invasive and does not provide the topographic specificity offered by fMRI. fMRI has been widely used for pre-

operative language mapping and the assessment of language lateralization, as it is noninvasive and offers topographic maps of language function with very high sensitivity and acceptable specificity (6, 17).

Some authors have casted questions on the accuracy of fMRI, especially in AVM patients. The hypothesized theory is that AVMs could reduce the cerebral perfusion around extranidal tissues (the so called "arterial steal"), resulting in abnormal fMRI results, as BOLD fMRI is dependent on blood oxygen levels (30). However, until recently, a number of studies compared fMRI and the Wada test or ESM, and the results have demonstrated that even in patients with vascular malformations, fMRI is an excellent method for language lateralization (5, 14, 22).

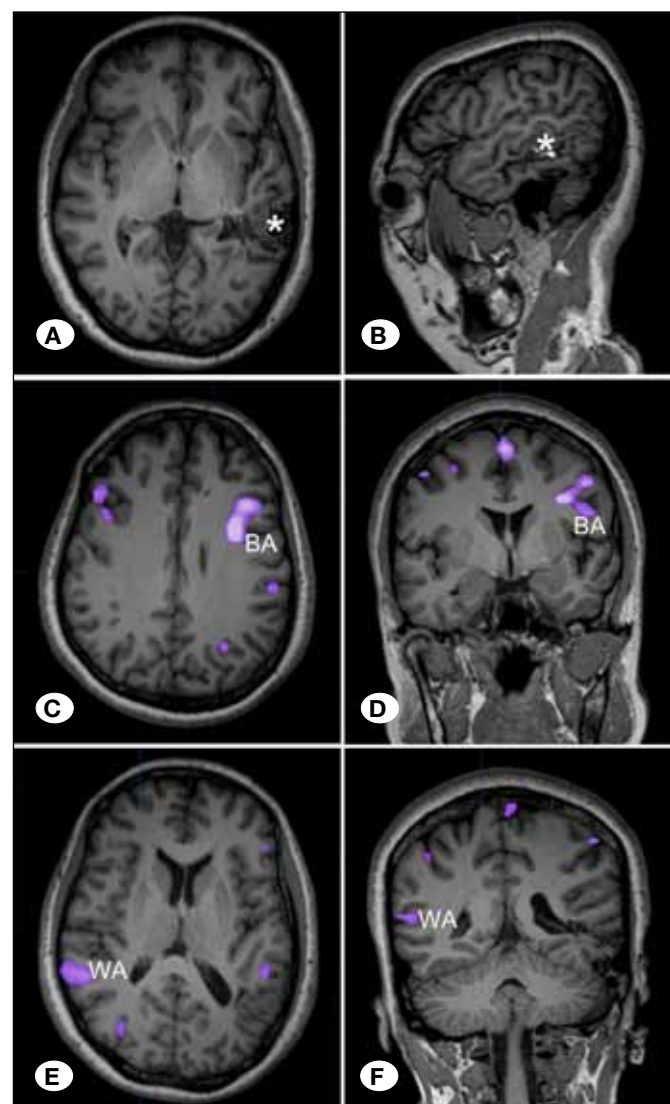


Figure 2: MRI of a patient in R Group, with lesions involving the Wernicke area (case 8). T1-weighted sagittal (A) and axial (B) MR images revealed an AVM (*) involving the Wernicke area. fMRI images demonstrated left-sided lateralization of the Broca area (C, D "BA") and right-sided lateralization of the Wernicke area (E, F "WA").

Table 1: Clinical, Imaging and Follow-Up Data of the 43 AVM Patients

Case No.	Age (yrs)	Sex	Main Presentation	S-M Grade	Lesion Location	Lesion Diameter (mm)	Language Lateralization		Language Function Before Surgery	Language Function at short-term follow-up	Language Function at long-term follow-up
							BA	WA			
R Group											
1	22	M	Seizure	3	BA	54.5	rt	lt	normal	normal	normal
2	26	F	Hemorrhage	2	BA	26.4	rt	lt	normal	normal	normal
3	27	M	Seizure	3	BA	36.7	rt	lt	normal	anomic aphasia	normal
4	55	M	Hemorrhage	3	BA	43.5	rt	rt	normal	motor aphasia	conduction aphasia
5	44	F	Headache	2	WA	28.6	lt	rt	normal	anomic aphasia	normal
6	50	M	Aphasia	3	WA	30.1	lt	rt	normal*	anomic aphasia	normal
7	27	F	Hemorrhage	3	WA	45.7	lt	rt	anomic aphasia	anomic aphasia#	normal
8	47	F	Hemorrhage	3	WA	36.9	lt	rt	normal	normal	normal
9	41	M	Hemorrhage	3	WA	37.4	lt	rt	normal	normal	normal
10	36	M	Seizure	3	WA	47.7	lt	rt	normal	normal	normal
11	41	M	Headache	2	WA	19.5	lt	rt	normal	normal	normal
12	27	M	Headache	3	WA	29.7	lt	rt	normal	normal	normal
13	26	M	Seizure	3	WA	27.6	lt	rt	normal	anomic aphasia	normal
14	20	M	Seizure	3	WA	48.2	lt	rt	normal	conduction aphasia	conduction aphasia
15	26	M	Hemorrhage	4	WA	66.1	lt	rt	normal	normal	normal
16	45	M	Hemorrhage	3	WA	37.1	lt	rt	normal	anomic aphasia	anomic aphasia
17	22	F	Seizure	3	WA	35.1	lt	rt	normal	normal	normal
18	41	F	Seizure	3	WA	53.2	lt	rt	normal	normal	normal
NR Group											
19	34	M	Dizziness	2	BA	9.8	lt	lt	normal	normal	normal
20	18	M	Seizure	4	BA	79.4	lt	lt	normal	transcortical motor aphasia	normal
21	25	M	Hemorrhage	3	BA	33.3	lt	lt	normal	normal	normal
22	27	M	Hemorrhage	3	BA	38	lt	lt	normal	anomic aphasia	normal
23	26	F	Seizure	2	BA	26.4	lt	lt	normal	normal	normal

Table 1: Cont.

Case No.	Age (yrs)	Sex	Main Presentation	S-M Grade	Lesion Location	Lesion Diameter (mm)	Language Lateralization		Language Function Before Surgery	Language Function at short-term follow-up	Language Function at long-term follow-up
							BA	WA			
24	28	M	Seizure	4	BA	62.8	It	It	normal	conduction aphasia	anomic aphasia
25	21	M	Hemorrhage	3	BA	55.4	It	It	normal	anomic aphasia	normal
26	12	M	Seizure	3	BA	38.5	It	It	normal	normal	normal
27	24	M	Seizure	2	BA	28.2	It	It	normal	normal	normal
28	45	M	Hemorrhage	3	WA	49	It	It	normal	normal	normal
29	45	M	Hemorrhage	3	WA	49.8	It	It	anomic aphasia	anomic aphasia#	normal
30	13	F	Headache	3	WA	58.4	It	It	normal	anomic aphasia	normal
31	21	M	Seizure	3	WA	31.3	It	It	normal	conduction aphasia	normal
32	25	M	Headache	3	WA	40.2	It	It	normal	normal	normal
33	44	F	Headache	4	WA	65.9	It	It	normal	normal	normal
34	13	M	Seizure	3	WA	25.2	It	It	normal	normal	normal
35	19	M	Hemorrhage	2	WA	23.3	It	It	normal	normal	normal
36	53	M	Seizure	3	WA	33.5	It	It	normal	normal	normal
37	33	M	Headache	4	WA	82.9	It	It	normal	anomic aphasia	normal
38	12	M	Hemorrhage	3	WA	34.2	It	It	normal	normal	normal
39	11	M	Hemorrhage	3	WA	38.9	It	It	normal	normal	normal
40	50	M	Dizziness	3	WA	30.3	It	It	normal	anomic aphasia	anomic aphasia
41	13	F	Hemorrhage	4	WA	69.3	It	It	normal	anomic aphasia	normal
42	19	F	Asymptomatic	3	WA	38.7	It	It	normal	conduction aphasia	conduction aphasia
43	31	F	Hemorrhage	3	WA	35.4	It	It	normal	conduction aphasia	anomic aphasia

BA: Broca area, **WA:** Wernicke area, **M:** Male, **F:** female, **rt:** Right, **lt:** Left, **R:** Right-sided lateralized, **NR:** Non right-sided lateralized, **yrs:** years, **S-M:** Spetzler-Martin, *The patient presented with transient aphasia but recovered at admission. #Although these two patients had aphasia after surgery, language evaluation showed no significant change compared to the preoperative language function.

The Clinical Significance of Right-sided Language Lateralization

Previous studies have shown language reorganization in the setting of various intracranial diseases, including AVMs (1, 16, 18, 32), strokes (21, 34), brain tumors (11, 23, 25, 33), epilepsies (2, 15), etc. The language reorganization in AVM patients has been of particular interest because it has been noticed that unruptured AVMs located in the language cortex usually do not lead to aphasia. In our previous study, 63 AVM patients were included and only 3 patients presented with language disorder (4.8%) (9). In this series, only 1 AVM patient without intracranial hemorrhage presented with transient aphasia before surgery (2.3%). This is different from other intracranial disorders. For example, for brain tumors involving the language areas, language dysfunction is a very common symptom.

Right-sided dominance is not a very rare phenomenon for AVM patients with lesions involving the language cortex (9, 17), and some studies have shown that the right hemisphere might be also very important in language processing (28, 29, 31). In our previous study, 23 of the 63 patients showed right-sided lateralization (36.5%), which was considered as suggesting language cortex reorganization (9). However, our previous study focused on the preoperative fMRI findings, and postoperative language functions were not evaluated. As a result, the significance of the right-sided lateralization and especially the effect on the language function outcome after surgery on BOLD fMRI are still unclear. Therefore, we conducted this study to evaluate if right-sided lateralization on preoperative fMRI could lower the incidence of language disorders after surgery. A series of 43 AVM patients with lesions involving language areas were retrospectively reviewed, and the language functions were systematically evaluated before surgery, at short-term follow-up and at long-term follow-up. On preoperative fMRI, right-sided lateralization was observed in 18 patients, and thus the incidence of right-sided lateralization was up to 41.9%. The high incidence might be attributed to that the AVM is a congenital lesion and develops before the period of language learning. When AVMs develop in the anatomical site of eloquent cortex in early life, neuroplasticity will result in cortical reorganization of the functional areas, with displacement to other regions, including the areas around the lesion on the same hemisphere and the homologous regions on the contralateral hemisphere.

However, although this right-sided lateralization in our study suggests language reorganization, follow-up language evaluation showed that there was no significant difference between the R Group and the NR Group, which means that right-sided lateralization on BOLD fMRI could not decrease the incidence of language dysfunction after surgery. We think there are two explanations for this phenomenon. First, although LI showed right-sided lateralization of these 18 patients, this does not mean there was no activation in the language areas on the left hemisphere. In contrast, BOLD signal activations were also observed in the traditional language areas on the left side, suggesting that these areas are still functional and

might even be essential for language function. The language areas on the right side may play only part of language function. Second, although previous studies showed the fMRI had a high concordance with the Wada test in determining language dominance, the results of fMRI might be unreliable, especially for those patients with atypical lateralization. We did not perform Wada tests in this series because of its invasive character, so the language lateralization cannot be confirmed.

Limitations of Study

The present study has several limitations. First, although we enrolled a large series of 43 AVM patients with nidus involving language areas, the sample size, might not be big enough to determine the difference of the two groups, which may lead to false-negative findings. Second, this is an fMRI study, and the confirmatory tests, ESM and Wada testing were not conducted.

CONCLUSION

Right-sided dominance is not a rare phenomenon for AVM patients with lesions involving the language cortex. Although right-sided lateralization suggests language reorganization, it does not decrease the incidence of language dysfunction after surgery. Neurosurgeons still need to pay attention to the language function protection in these patients.

ACKNOWLEDGMENT

This study received a grant from the Ministry of Science and Technology of China (2011BAI08B08 and 2012CB825505), National Key Technology Research and Development Program of the Ministry of Science and Technology of China (2013BAI09B03), and Center of Stroke, Beijing Institute for Brain Disorders (BIBD-PXM2013_014226_07_000084).

REFERENCES

1. Alkadhi H, Kollias SS, Crelier GR, Golay X, Hepp-Reymond MC, Valavanis A: Plasticity of the human motor cortex in patients with arteriovenous malformations: A functional MR imaging study. *AJNR Am J Neuroradiol* 21:1423-1433,2000
2. Baciú M, Perrone-Bertolotti M: What do patients with epilepsy tell us about language dynamics? A review of fMRI studies. *Rev Neurosci* 26:323-341, 2015
3. Bauer PR, Reitsma JB, Houweling BM, Ferrier CH, Ramsey NF: Can fMRI safely replace the Wada test for preoperative assessment of language lateralisation? A meta-analysis and systematic review. *J Neurol Neurosurg Psychiatry* 85:581-588, 2014
4. Bub DN, Arguin M, Lecours AR: Jules Dejerine and his interpretation of pure alexia. *Brain Lang* 45:531-559, 1993
5. Cannestra AF, Pouratian N, Forage J, Bookheimer SY, Martin NA, Toga AW: Functional magnetic resonance imaging and optical imaging for dominant-hemisphere perisylvian arteriovenous malformations. *Neurosurgery* 55:804-812; discussion 812-814, 2004

6. Chen P, Lin J, Chen B, Lu C, Guo T: Processing emotional words in two languages with one brain: ERP and fMRI evidence from Chinese-English bilinguals. *Cortex* 71:34-48, 2015
7. Choi JH, Mohr JP: Brain arteriovenous malformations in adults. *Lancet Neurol* 4:299-308, 2005
8. Christman SD, Prichard EC, Corser R: Factor analysis of the Edinburgh Handedness Inventory: Inconsistent handedness yields a two-factor solution. *Brain Cogn* 98:82-86, 2015
9. Deng X, Zhang Y, Xu L, Wang B, Wang S, Wu J, Zhang D, Wang R, Wang J, Zhao J: Comparison of language cortex reorganization patterns between cerebral arteriovenous malformations and gliomas: A functional MRI study. *J Neurosurg* 122:996-1003, 2015
10. Dickey MW, Warren T: The influence of event-related knowledge on verb-argument processing in aphasia. *Neuropsychologia* 67:63-81, 2015
11. Duffau H: The huge plastic potential of adult brain and the role of connectomics: New insights provided by serial mappings in glioma surgery. *Cortex* 58:325-337, 2014
12. Gold R, Faust M, Ben-Artzi E: Metaphors and verbal creativity: The role of the right hemisphere. *Laterality* 17:602-614, 2012
13. Hagoort P: Nodes and networks in the neural architecture for language: Broca's region and beyond. *Curr Opin Neurobiol* 28:136-141, 2014
14. Janecek JK, Swanson SJ, Sabsevitz DS, Hammeke TA, Raghavan M, E Rozman M, Binder JR: Language lateralization by fMRI and Wada testing in 229 patients with epilepsy: Rates and predictors of discordance. *Epilepsia* 54:314-322, 2013
15. Janszky J, Mertens M, Janszky I, Ebner A, Woermann FG: Left-sided interictal epileptic activity induces shift of language lateralization in temporal lobe epilepsy: An fMRI study. *Epilepsia* 47:921-927, 2006
16. La Piana R, Klein D, Cortes M, Tampieri D: Speech reorganization after an AVM bleed cured by embolization. A case report and review of the literature. *Interv Neuroradiol* 15:456-461, 2009
17. Lee DJ, Pouratian N, Bookheimer SY, Martin NA: Factors predicting language lateralization in patients with perisylvian vascular malformations. *Clinical article. J Neurosurg* 113:723-730, 2010
18. Lehericy S, Biondi A, Sourour N, Vlaicu M, du MST, Cohen L, Vivas E, Capelle L, Faillot T, Casasco A, Le Bihan D, Marsault C: Arteriovenous brain malformations: Is functional MR imaging reliable for studying language reorganization in patients? Initial observations. *Radiology* 223:672-682, 2002
19. Mesulam MM, Thompson CK, Weintraub S, Rogalski EJ: The Wernicke conundrum and the anatomy of language comprehension in primary progressive aphasia. *Brain* 138:2423-2437, 2015
20. Mohr JP: Brain arteriovenous malformations: Children and adults. *Stroke* 36:2060-2061, 2005
21. Otal B, Olma MC, Floel A, Wellwood I: Inhibitory non-invasive brain stimulation to homologous language regions as an adjunct to speech and language therapy in post-stroke aphasia: A meta-analysis. *Front Hum Neurosci* 9:236, 2015
22. Pouratian N, Bookheimer SY, Rex DE, Martin NA, Toga AW: Utility of preoperative functional magnetic resonance imaging for identifying language cortices in patients with vascular malformations. *J Neurosurg* 97:21-32, 2002
23. Rosler J, Niraula B, Strack V, Zdunczyk A, Schilt S, Savolainen P, Lioumis P, Makela J, Vajkoczy P, Frey D, Picht T: Language mapping in healthy volunteers and brain tumor patients with a novel navigated TMS system: Evidence of tumor-induced plasticity. *Clin Neurophysiol* 125:526-536, 2013
24. Rutten GJ, Ramsey NF, van Rijen PC, Alpherts WC, van Veelen CW: fMRI-determined language lateralization in patients with unilateral or mixed language dominance according to the Wada test. *Neuroimage* 17:447-460, 2002
25. Sanai N, Mirzadeh Z, Berger MS: Functional outcome after language mapping for glioma resection. *N Engl J Med* 358:18-27, 2008
26. Spotorno S, Faure S: Change detection in complex scenes: Hemispheric contribution and the role of perceptual and semantic factors. *Perception* 40:5-22, 2011
27. Stapleton CJ, Walcott BP, Fusco MR, Thomas AJ, Ogilvy CS: Brain mapping for safe microsurgical resection of arteriovenous malformations in eloquent cortex. *World Neurosurg* 83:1148-1156, 2015
28. Taylor KI, Regard M: Language in the right cerebral hemisphere: Contributions from reading studies. *News Physiol Sci* 18:257-261, 2003
29. Turkeltaub PE, Coslett HB, Thomas AL, Faseyitan O, Benson J, Norise C, Hamilton RH: The right hemisphere is not unitary in its role in aphasia recovery. *Cortex* 48:1179-1186, 2012
30. Ulmer JL, Hacein-Bey L, Mathews VP, Mueller WM, DeYoe EA, Prost RW, Meyer GA, Krouwer HG, Schmainda KM: Lesion-induced pseudo-dominance at functional magnetic resonance imaging: Implications for preoperative assessments. *Neurosurgery* 55:569-579; discussion 580-581, 2004
31. Van Ettinger-Veenstra H, Ragnehed M, McAllister A, Lundberg P, Engstrom M: Right-hemispheric cortical contributions to language ability in healthy adults. *Brain Lang* 120:395-400, 2012
32. Vikingstad EM, Cao Y, Thomas AJ, Johnson AF, Malik GM, Welch KM: Language hemispheric dominance in patients with congenital lesions of eloquent brain. *Neurosurgery* 47:562-570, 2000
33. Wang L, Chen D, Yang X, Olson JJ, Gopinath K, Fan T, Mao H: Group independent component analysis and functional MRI examination of changes in language areas associated with brain tumors at different locations. *PLOS ONE* 8:e59657, 2013
34. Winhuisen L, Thiel A, Schumacher B, Kessler J, Rudolf J, Haupt WF, Heiss WD: Role of the contralateral inferior frontal gyrus in recovery of language function in poststroke aphasia: a combined repetitive transcranial magnetic stimulation and positron emission tomography study. *Stroke* 36:1759-1763, 2005