



DOI: 10.5137/1019-5149.JTN.16956-16.1

Received: 05.01.2016 / Accepted: 16.02.2016

Published Online: 04.03.2016

Original Investigation

# Preventing Sciatic Nerve Injury due to Intramuscular Injection: Ten-Year Single-Center Experience and Literature Review

Sirma GEYİK<sup>1</sup>, Murat GEYİK<sup>2</sup>, Remzi YIGITER<sup>1</sup>, Samiye KUZUDISLI<sup>3</sup>, Sadullah SAGLAM<sup>4</sup>, Mehmet Ali ELCI<sup>5</sup>, Mustafa YILMAZ<sup>6</sup>

<sup>1</sup>Gaziantep University, School of Medicine, Department of Neurology, Gaziantep, Turkey

<sup>2</sup>Gaziantep University, School of Medicine, Department of Neurosurgery, Gaziantep, Turkey

<sup>3</sup>Zirve University, EBN School of Medicine, Department of Neurology, Gaziantep, Turkey

<sup>4</sup>Adiyaman University, School of Medicine, Department of Neurology, Adiyaman, Turkey.

<sup>5</sup>Kırıkhan State Hospital, Department of Neurology, Antakya, Turkey

<sup>6</sup>Fatih University, School of Medicine, Department of Neurology, Istanbul, Turkey

## ABSTRACT

**AIM:** Sciatic nerve injury is the most frequent and serious complication of intramuscular gluteal injection. This study aims to highlight the incidence and causes of this continuing problem and to discuss the relevant literature.

**MATERIAL and METHODS:** A total of 217 subjects who were diagnosed with sciatic nerve injury in our neurophysiology laboratory between 2003 and 2013 were examined. Sensory and motor transmission studies and needle electromyography were performed by conventional methods in the two lower legs and the results were compared between each leg.

**RESULTS:** Of the subjects who experienced a sciatic injury secondary to intramuscular injection, 59 (27.2%) were female and 158 (72.8%) were male. In all subjects, the dorsogluteal site of the buttocks was selected for intramuscular injection. Sciatica occurred on the right side in 91 subjects, on the left side in 125, and bilaterally in one. The peroneal nerve was more affected than the tibial nerve. The most used agents were non-steroidal anti-inflammatory drugs. According to follow-up electromyography findings of 103 subjects, significant sequelae remained in 2/3 of cases.

**CONCLUSION:** The occurrence of sciatic neuropathy after gluteal injection causing permanent sequelae and leading to medicolegal problems is relatively rare. We suggest a double quadrant drawing technique in each gluteal region. We also draw attention to this issue with postgraduate and in-service training programs of medical staff, and providing continuity in education can reduce this serious complication.

**KEYWORDS:** Intramuscular injection, Sciatic nerve injury, Electrophysiology, Malpractice

## INTRODUCTION

The sciatic nerve (SN) is positioned lateral and downward along the pelvis inner wall and leaves the pelvis from the great sciatic notch (14). It comprises two separate trunci: lateral truncus (fibular division) and medial truncus (tibial division) (7). SN is open to trauma because of its posterolateral position, smaller amount of supporting connective tissue,

and anatomical variations (13). The accepted mechanisms of injury include direct needle trauma, secondary constriction by scar, penetrating injuries of popliteal fossa and neurotoxic chemicals in the injected agent (10, 11). Rules of parenteral drug application are universal. In the literature, the most common used sites for intramuscular (IM) injection are dorsogluteal (DG), ventrogluteal (VG), vastus lateralis, and deltoid muscles (22). Application conditions, standards of

qr code

Corresponding author: Sirma GEYİK

E-mail: drsirmageyik@hotmail.com

technical facilities, and quality of service create differences in how an injection is administered. When IM gluteal injections are not correctly administered, the most frequent and serious complication is sciatic nerve neuropathy (SNN) (19).

Injection-induced SNN causes significant sequelae, and iatrogenic and medicolegal consequences. In this study, we reviewed the database of 217 patients with injection-induced SNN referred for electrodiagnostic studies and present the results with a discussion of the literature.

## ■ MATERIAL AND METHODS

### Sample and Selection

The local ethics committee approved this study. A total of 217 subjects who were diagnosed with sciatic injury in our neurophysiology laboratory between 2003 and 2013 were retrospectively examined. Neurological and electrophysiological examinations of the subjects were performed by neurologists.

### Data sources

Sensory and motor transmission studies and needle electromyography were performed by conventional methods in the two lower legs while paying attention to the heat of the extremity with a Keypoint 4m/4c device (Medtronic, USA). In motor transmission studies, the compound muscle action potential (CMAP) was recorded from the extensor digitorum brevis muscle by stimulating the peroneal nerve in the wrist, fibular neck, and below the knee and from the abductor hallucis muscle by stimulating nervus tibialis in the medial malleolus and below the knee. Nervus tibialis and peroneal nerve constitute the nervus sciaticus, which is situated in the same nerve sheath. Therefore, motor innervation evaluation of SN is achieved via these aforementioned muscles, which are peripherally and superficially located. Distal latency, transmission velocity, and CMAP amplitude were evaluated in motor transmission examinations. In sensory transmission examinations, the sensory action potential (SAP) was recorded from the lateral malleolus by stimulating nervus suralis (a sensory branch that is formed by a united branch of nervus tibialis and the peroneal nerve) at a distance that is 14 cm away from the cruris to the recording electrode; SAP was recorded from the front face of the wrist by stimulating peroneal nerve at a distance that is 12 cm away from superficialis cruris to the recording electrode. Sensory measurements were conducted in an antidromic manner. Distal latency and SAP amplitude were evaluated in sensory transmission measurements. Amplitude values in responses recorded in the extremities with and without complaints were compared. Needle electromyography (EMG) was performed on tibialis anterior, extensor hallucis longus, peroneus longus, peroneus brevis, medial head of gastrocnemius, and short head of biceps femoris with bilateral extremities. Subjects who did not have sciatic pain or objective findings after injection and had normal electrophysiological findings were excluded. Electroneuromyography (ENMG) was performed in 103 patients who had been followed after 6–12 months.

Descriptive statistical analyses were used to present the study population and to describe the subgroups.

## ■ RESULTS

Among subjects who demonstrated sciatic injury resulting from IM injection, 59 (27.2%) were female and 158 (72.8%) were male. A total of 39 out of 217 patients (18%) were between 0 and 16 years (three of these between 0 and 4 years), 122 patients (56%) were between 17 and 64 years, and 56 patients (26%) were over 65 years (Table I). In all subjects, the DG site of the buttocks was selected for IM injection. Of 169 patients for whom injections were administered by known individuals, 140 had received injection from the medical staff, 27 from infirm individuals in prone position, and two had injected themselves in the lateral position. Sciatic involvement was present on the right side in 91 subjects (42.4%), on the left side in 125 (57.2%), and bilaterally in one. In the bilateral SNN subject, two different injections, which were performed by different health workers in the same department within a 12-h interval, had been incorrectly performed at a quarter of the distance from the lower inner quadrant of the gluteal region, which was detected by tracing the injection needle in the acute phase.

According to clinical and electrophysiological SNN evaluations, the peroneal nerve was the predominant nerve that was affected in 125 patients, the tibial nerve in 60, and both peroneal and tibial nerves were evenly affected in 32 (Table II). The most widely used drug classes in the injection were

**Table I:** Age and Gender Distribution of the Patients with Sciatic Nerve Neuropathy (n=217)

Characteristics	n	(%)
<b>Age (years)</b>		
0–16	39	18
17–64	122	56
>64	56	26
<b>Gender</b>		
Male	158	72.8
Female	59	27.2

**Table II:** Distribution of Involvement in the Branches of the Sciatic Nerve (n=217)

Characteristics	n	(%)
<b>Peroneal Nerve</b>		
Right	50	23
Left	75	34.5
<b>Tibial Nerve</b>		
Right	28	12.9
Left	32	14.7
<b>Equal</b>	<b>32</b>	<b>14.7</b>

non-steroidal anti-inflammatory drugs (NSAIDs) in 62 subjects, metamizole in 32, antibiotics in 36, combined drug categories in six, diazepam in two, and an unknown substance in 72. Various other drugs were used in 7 subjects (Table III). Out of 217 subjects, polyneuropathy and poliomyelitis were observed in 23 and 2 subjects, respectively. With respect to distribution of cases by year, complications more frequently occurred in the first 3 years (Figure 1). Interestingly none of the cases underwent surgery for treatment. According to the second ENMG results (min 3-max 8 months after the first ENMG) in the follow-up of 103 subjects returning for pain control, there was no change in 32 patients. Partial electrophysiological recovery was noticed in 45 cases, and significant electrophysiological recovery in 36 cases.

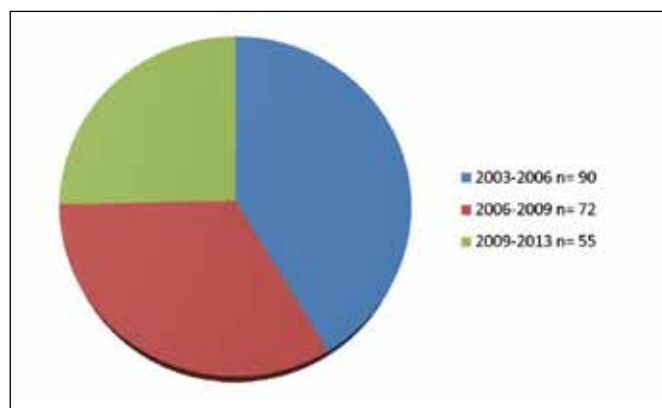
## DISCUSSION

Because of their large muscle mass and lack of major blood vessels and nerves, the gluteus maximus and medius muscles are preferred for IM injections in adults. SNN resulting from an injection occurs at a 2.7% rate (28). However, recently, there have been few publications regarding SN injury from IM injection. It is unclear whether this problem has been largely overcome. Approximately 20% of injection-related peripheral nerve injuries occur in the gluteal region (27). Villarejo and

**Table III:** Parenteral Drug Categories Injected into Patients with Sciatic Nerve Neuropathy (n=217)

Drugs	n	(%)
NSAID	62	28.5
Metamizole	32	14.7
Antibiotics	36	16.5
NSAID+Antibiotics	6	2.8
Diazepam	2	0.9
Others	7	3.2
Unknown	72	33.1

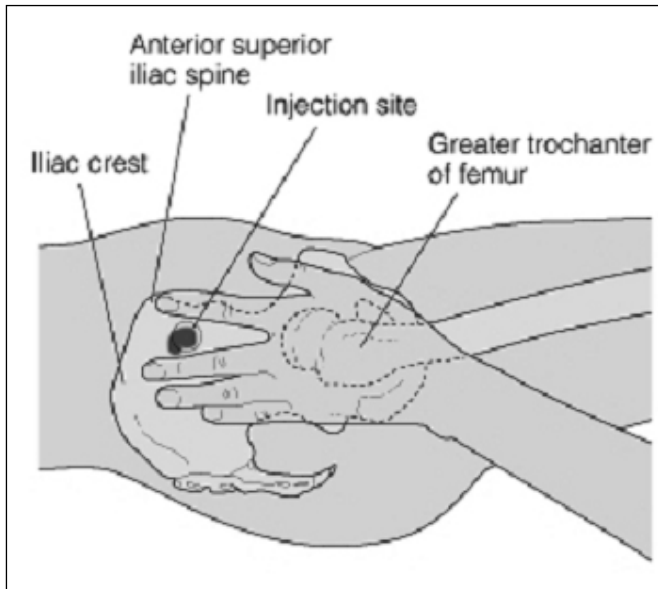
**NSAID:** Non-steroidal anti-inflammatory drug.



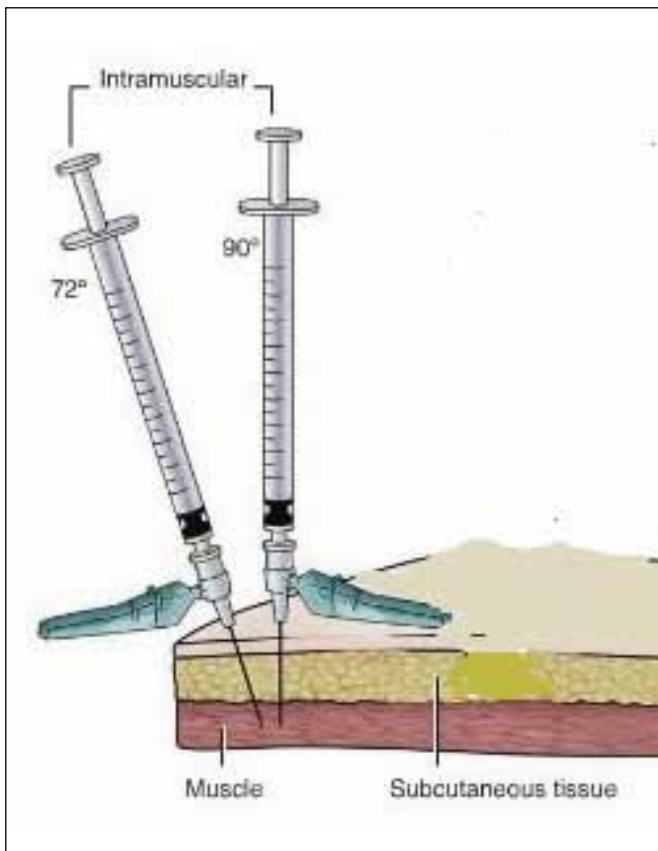
**Figure 1:** The distribution of patients by years (2003-2013).

Pascual published a study with 370 subjects with injection-dependent SNN; Obach et al. published data obtained from 131 subjects with similar lesion (6, 24). A retrospective study based on 24 years of records found 1,025 patients with lower extremity lesions, of which 136 (13%) were injection-related nerve injuries (9). SNN as determined by clinical and electrophysiological methods was present in all 217 patients analyzed in our study. In our electrophysiology laboratory, an annual average of 3,000 ENMGs are performed. Injection neuropathy was diagnosed in 0.7% of all cases receiving an ENMG. Despite excluding subjects without injection-related objective findings, the number of patients included in our study was high. This highlights injection-related SNN as still being a serious clinical problem, with the potential to cause financial and labor losses. Medicolegal reports revealed that the medical staff and hospital management have been heavily financially penalized for this malpractice (13). Mechanical, ischemic, and toxic mechanisms have been linked to injection-related SNN pathogenesis (15, 17). Mechanical trauma may occur through direct nerve injury from the point of injecting the needle or by intramuscular hematoma pressure. Direct trauma, which is the most common and important cause of SNN, is manifested because of injection to the wrong site (4). Emerging clinical symptoms as a result of the SN injury are often observed immediately following injection. (18, 19). Long-term effects occurred following intramuscular injection depend on the administered drug shifting towards the SN under the gluteus maximus muscle, with a tendency to create stasis. In the days or weeks following intramuscular injection, slow destruction of the SN fascicles develop due to drug exposure (24, 27).

The exact IM injection site, length and angle of the injection needle, muscle size and volume, and thickness of the tissue and fat layers at the injection site are all potential factors determining SN injury. In the recent literature, some authors have stated the DG site to be unsafe (21, 22). This site is commonly used over other injection sites in routine clinical practice (3). In an investigation of IM injection practice involving 593 nurses, 48% were not taught about the VG site in their basic education (Figure 2) (1). In our retrospective study, the DG site had been used in all cases, thus further highlighting dependency on DG injection. Injection neuropathy was observed less in women than in men (approximately 1/3 ratio) possibly because subcutaneous adipose tissue of the gluteal region of women is larger than that of men; hence, the gluteal region typically has a greater volume (25). The fact that 23 of our patients had additional polyneuropathy may be because the SN in these patients was more sensitive to trauma, ischemic, and toxic effects. In this study, 33 subjects were children (18%), with the youngest age that we could include being 4 years because injections are not usually administered to the gluteal region of children below this age. The vastus lateralis or rectus femoris muscles are appropriate choices for injections in very young children where the gluteal region is not feasible or in general when there is a local infection at the favored injection site, or weakness, cachexia, or polyneuropathy in subjects exposed to the injection (5). The needle angle and drug volume are other important factors for SN injury. Injections administered at 72°



**Figure 2:** Ventrogluteal region, the palm of the opposing hand is placed on the greater trochanter and the index finger on the anterior superior iliac spine. A triangle is formed with the middle finger pointing towards the iliac crest. The injection site is the centre of the triangle.

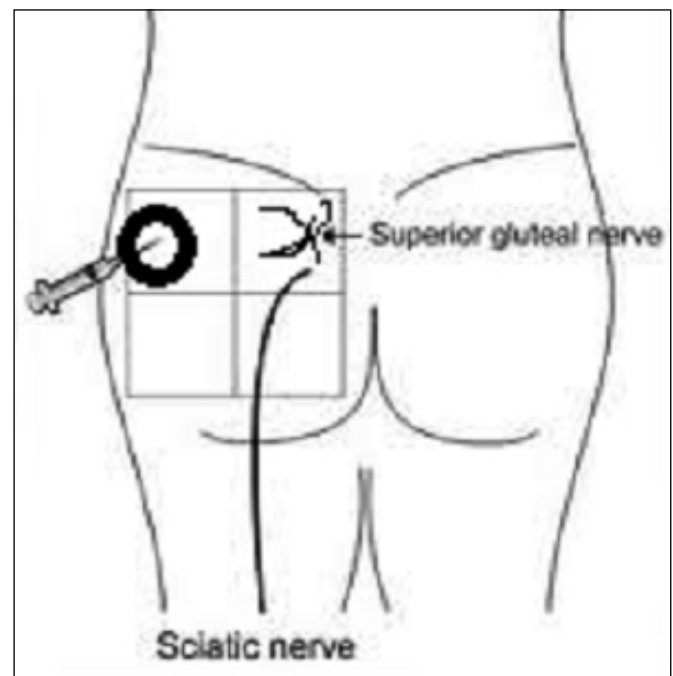


**Figure 3:** 90° angle maximizes the depth of penetration into the muscle, an injection given at 72° reaches 95% of the depth of one given at 90°.

reach 95% of depth of those given at 90°. This difference is not significant, and therefore the angle for applying the injection was recommended to be between 72°–90° (Figure 3) (8). The authors of this study suggested that the maximum volume should be between 3 and 5 ml (16, 22). Another important factor delineating the formation of injection neuropathies is the type of drug administered (5). While in previous studies, penicillin, diazepam, and chlorpromazine were the most significant agents causing SNN, anti-inflammatory drugs, other antibiotics, pyrazoline, quinine, and tetanus toxoid can also cause SNN (13, 20, 26). In our study, NSAIDs, antibiotics, and analgesics were most commonly used agents. In our cases, approximately 12% of the injections were administered by unauthorized individuals and thus indicate a serious medicolegal problem in Turkey.

The peroneal region is typically more affected than the tibial portion in SNN (12, 29) because the lateral portion (peroneal) is larger than the medial (tibial) portion, contains less fascicles and connective tissue, and the medial portion is more protected via its inner location (2). Similar to the literature (13, 29), we found that the peroneal division was more involved in 58.8% of the cases.

Conservative treatment, early neurolysis and irrigation with normal saline, or late surgical neurolysis and grafting (if required) are treatment options for injection-dependent SNN (23, 24). Partial improvement (without therapy) was observed in subjects at a 30% rate at 1 year, 50% at 2 years, and 75% at 3 years for sciatic neuropathies (29). In our study, none of the cases underwent surgery for treatment. 154 (72%) of cases underwent physiotherapy and received symptomatic treatment. Follow-up ENMG was performed in 103 patients



**Figure 4:** The dorsogluteal site is located in the superior lateral aspect of the gluteal muscles.

and only in 36 cases was significant electrophysiological recovery observed.

The absence of radiological verification in all patients with sciatic nerve neuropathy is the limitation of this study.

## ■ CONCLUSION

In daily practice the DG site is most commonly used. With the technique of classical intramuscular injection, the index finger is placed on the anterior superior iliac spine and the thumb is placed on the skin of the gluteal region. We suggest that this technique used to determine accurate location of intramuscular practice in protecting from injury to the SN is not sufficiently effective. In gluteal intramuscular injections, we suggest dividing each gluteal region into four quadrants twice (double quadrant drawing technique) (Figure 4). We also suggest that taking measures to prevent incompetent individuals from giving injections and improving continuity in the education of medical staff on this subject in postgraduate and in-service training programs may reduce the incidence of this serious complication.

## ■ REFERENCES

1. Beecroft PC, Redick SA: Intramuscular injection practices of pediatric nurses: Site selection. *Nurse Educ* 15: 23-28, 1990
2. Berihu BA, Debeb YG: Anatomical variation in bifurcation and trifurcations of sciatic nerve and its clinical implications: In selected university in Ethiopia. *BMC Res Notes* 8:633,2015
3. Engstrom JL, Giglio NN, Takacs SM, Ellis MC, Cherwenka DI: Procedures used to prepare and administer intramuscular injections: A study of infertility nurses. *J Obstet Gynecol Neonatal Nurs* 29:159-168,2000
4. Gentili F, Hudson A, Kline DG, Hunter D: Peripheral nerve injection injury: An experimental study. *Neurosurgery* 4:244-253,1979
5. Gentili F, Hudson AR, Hunter D: Clinical and experimental aspects of injection injuries of peripheral nerves. *Can J Neurol Sci* 7:143-151,1980
6. Hornig C, Dorndorf W: Combined nerve damage and drug-induced cutaneous embolism after faulty intragluteal injection. *Dtsch Med Wochenschr* 108:221-223,1983
7. Katirji B: Peroneal neuropathy. *Neurol Clin* 17:567-591, vii,1999
8. Katsma D, Smith G: Analysis of needle path during intramuscular injection. *Nurs Res* 46:288-292,1997
9. Kline DG, Kim D, Midha R, Harsh C, Tiel R: Management and results of sciatic nerve injuries: A 24-year experience. *J Neurosurg* 89:13-23, 1998
10. Kotwal A, Priya R, Thakur R, Gupta V, Kotwal J, Seth T: Injection practices in a metropolis of North India: Perceptions, determinants and issues of safety. *Indian J Med Sci* 58:334-344, 2004
11. Maqbool W, Sheikh S, Ahmed A: Clinical, electrophysiological, and prognostic study of postinjection sciatic nerve injury: An avoidable cause of loss of limb in the peripheral medical service. *Ann Indian Acad Neurol* 12:116-119, 2009
12. McIntosh KA, Preston DC, Logigian EL: Short-segment incremental studies to localize ulnar nerve entrapment at the wrist. *Neurology* 50:303-306, 1998
13. Mishra P, Stringer MD: Sciatic nerve injury from intramuscular injection: A persistent and global problem. *Int J Clin Pract* 64:1573-1579, 2010
14. Moayeri N, van Geffen GJ, Bruhn J, Chan VW, Groen GJ: Correlation among ultrasound, cross-sectional anatomy, and histology of the sciatic nerve: A review. *Reg Anesth Pain Med* 35:442-449, 2010
15. Napiontek M, Ruszkowski K: Paralytic drop foot and gluteal fibrosis after intramuscular injections. *J Bone Joint Surg Br* 75:83-85, 1993
16. Nicoll LH, Hesby A: Intramuscular injection: An integrative research review and guideline for evidence-based practice. *Appl Nurs Res* 15: 149-162, 2002
17. Obach J, Aragonés JM, Ruano D: The infrapiriformis foramen syndrome resulting from intragluteal injection. *J Neurol Sci* 58:135-142, 1983
18. Ong MJ, Lim GH, Kei PL: Clinics in diagnostic imaging (140). Iatrogenic sciatic nerve injury secondary to intramuscular injection. *Singapore Med J* 53: 551-554; quiz 555, 2012
19. Ramtahal J, Ramlakhan S, Singh K: Sciatic nerve injury following intramuscular injection: A case report and review of the literature. *J Neurosci Nurs* 38:238-240, 2006
20. Razinskas G, Lechner W: Embolia cutis medicamentosa following intramuscular injection of pyrazolone-containing preparations. *Z Hautkr* 60:1639-1645, 1985
21. Shaw A: Choosing the right injection site. *Nurs N Z* 8:18-19, 2002
22. Small SP: Preventing sciatic nerve injury from intramuscular injections: literature review. *J Adv Nurs* 47: 287-296, 2004
23. Topuz K, Kutlay M, Simsek H, Atabey C, Demircan M, Senol Guney M: Early surgical treatment protocol for sciatic nerve injury due to injection-a retrospective study. *Br J Neurosurg* 25:509-515, 2011
24. Villarejo FJ, Pascual AM: Injection injury of the sciatic nerve (370 cases). *Childs Nerv Syst* 9:229-232, 1993
25. Wells JC: Sexual dimorphism of body composition. *Best Pract Res Clin Endocrinol Metab* 21:415-430, 2007
26. Yaffe B, Pri-Chen S, Lin E, Engel J, Modan M: Peripheral nerve injection injury: An experimental pilot study of treatment modalities. *J Reconstr Microsurg* 3:33-37, 1986
27. Yeremeyeva E, Kline DG, Kim DH: Iatrogenic sciatic nerve injuries at buttock and thigh levels: The Louisiana State University experience review. *Neurosurgery* 65: A63-66, 2009
28. Yuen EC, Olney RK, So YT: Sciatic neuropathy: Clinical and prognostic features in 73 patients. *Neurology* 44:1669-1674, 1994
29. Yuen EC, So YT, Olney RK: The electrophysiologic features of sciatic neuropathy in 100 patients. *Muscle Nerve* 18:414-420, 1995