

*Case Report*

Pituitary Apoplexy due to the Diagnostic Test in a Cushing's Disease Patient

Fatih KUZU¹, Mustafa UNAL¹, Sanser GUL², Taner BAYRAKTAROGLU¹¹Bulent Ecevit University, Faculty of Medicine, Department of Endocrinology and Metabolism, Zonguldak, Turkey²Bulent Ecevit University, Faculty of Medicine, Department of Neurosurgery, Zonguldak, Turkey**ABSTRACT**

Pituitary apoplexy is a medical condition that needs urgent diagnosis and treatment. It may occur spontaneously or may be precipitated by a variety of reasons including dynamic endocrine tests. Although pituitary apoplexy is usually seen in non-functional pituitary adenoma, it can also be seen in ACTH secreting macroadenomas. ACTH secreting adenomas present usually as microadenomas and in these patients apoplexy is rarely seen. In this paper we present a 30-year-old male patient with a history of Cushing's disease who suffered from pituitary apoplexy after the 1 mg dexamethasone suppression test. He underwent endoscopic endonasal transsphenoidal surgery and his symptoms and signs were significantly improved.

KEYWORDS: Pituitary apoplexy, Cushing disease, Dexamethasone suppression test

■ INTRODUCTION

Cushing's syndrome is a very rare endocrine disorder with a 2-3 per million incidence that results from chronic exposure to hypercortisolism (1). Cushing's disease is caused by excessive secretion of adrenocorticotrophic hormone (ACTH) originating from a microadenoma (tumor size <1 cm) in 85-87% of the cases and a macroadenoma (tumor size >1 cm) in 13-15% (10).

Apoplexy occurs most commonly (>70 % of all cases) in non-functional pituitary macroadenomas with an incidence of 1.6-12.8% (14) and also in growth hormone and prolactin secreting adenomas (9). It can be seen almost at any age, usually spontaneously but sometimes precipitating condition can also be detected. (4). ACTH secreting adenomas present usually as microadenomas and in these patients apoplexy is rarely seen.

We herein present a patient with Cushing's disease who had pituitary apoplexy after the dexamethasone suppression test.

■ CASE REPORT

A 30-year-old man complained of headache and closure of the left upper eyelid. He had been evaluated due to headache two years ago and a non-functional macroadenoma of pituitary was detected (Figures 1A,B; 2A-C). He was re-evaluated and serum levels of cortisol were not suppressed with dexamethasone and the ACTH level was also normal. (Table I). One day after the dexamethasone suppression test he presented with severe headache and ptosis of the left upper eyelid with sudden loss of vision in the same eye (Figure 1A,B). Magnetic resonance imaging of the hypophysis showed definitive pituitary apoplexy and macroadenoma (Figure 2A-C). Hemorrhagic diathesis tests were normal. He was treated successfully by endoscopic endonasal transsphenoidal surgery within several hours after the onset of pituitary apoplexy. His symptoms and signs were significantly improved (Figure 1A,B). Microscopically, the tumor cells were monotonous round cells with a disrupted reticulin pattern that showed 70% immunoreactivity for ACTH (Figure 3A-C). His sight and ptosis recovered, but he developed panhypopituitarism and was given replacement treatment with glucocorticoids, levothyroxine and androgen (Table I).

**Corresponding author:** Mustafa UNAL**E-mail:** drmunal@yahoo.com

DISCUSSION

Pituitary apoplexy is a clinical syndrome secondary to rapid expansion of the content of the sella and extension to suprasellar region, cavernous sinus and sphenoid sinus due to bleeding, ischemic or mixed episode (ischemic and hemorrhagic) taking place within the pituitary adenoma (16). Risk factors for apoplexy include trauma, increased intracranial pressure, using anticoagulants, bromocriptine treatment, diabetic ketoacidosis, conventional angiography, radiotherapy

and open cardiac surgery. Pituitary apoplexy during pregnancy can occur because of hypertrophy of the pituitary gland in the lack of adenoma (5,15).

In a retrospective study from Romania, out of 98 patients with pituitary apoplexy (F:M=1.7:1), 64 (65.3%) patients had non-functional pituitary tumor, 24 (24.5%) had prolactinoma, 7 (7.1%) had growth hormone-secreting tumor and 3 (3.1%) had ACTH-secreting tumor (16). Generally, frequency of apoplexy is low in ACTH-secreting pituitary adenomas (3).

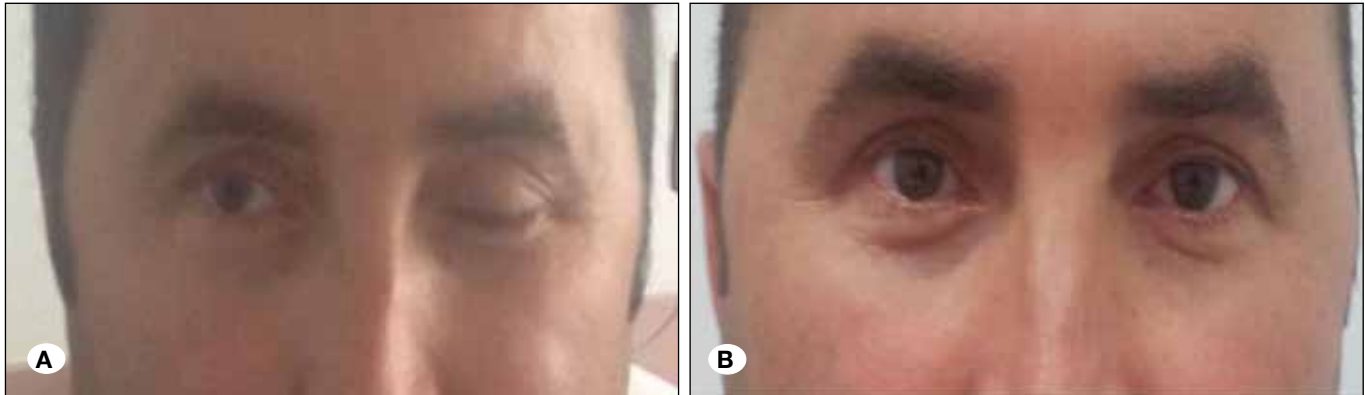


Figure 1: Unilateral ptosis before (A) and after (B) surgery

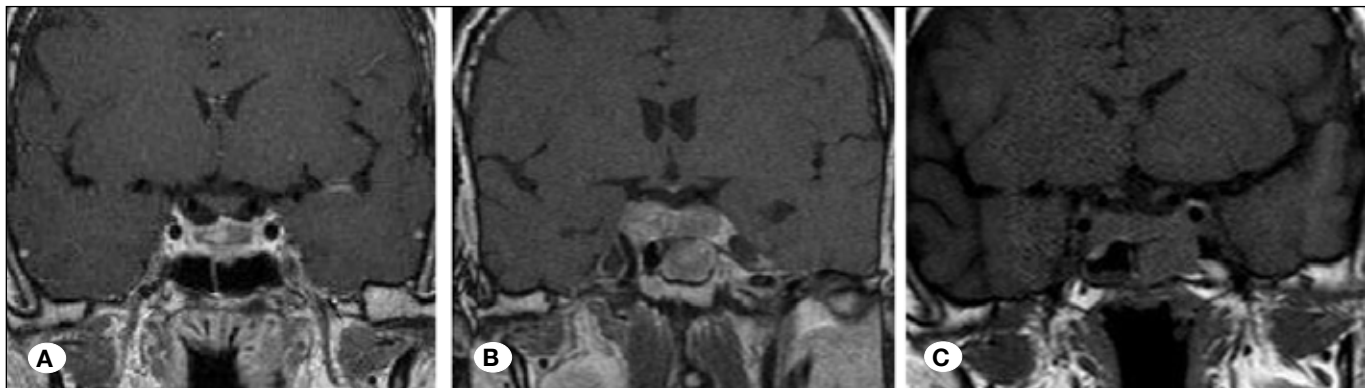


Figure 2: T1-weighted MRI (coronal view) shows a sellar and suprasellar mass with a hyperintense hemorrhage (A-B preoperative images, C after operation).

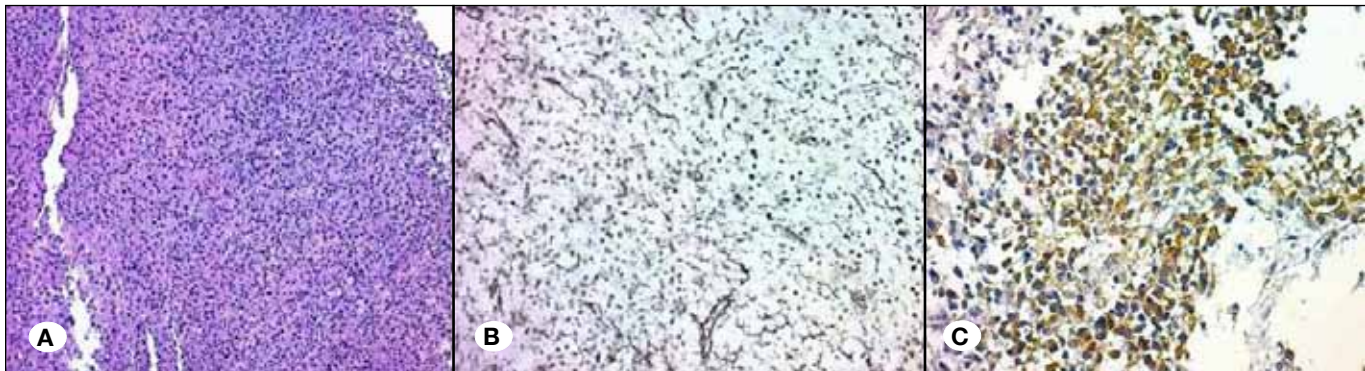


Figure 3: Histopathologic findings of pituitary tumor: A) Corticotroph adenoma displaying sheets of monotonous round cells (H&E, x100). B) Disrupted reticulin pattern in adenoma (Reticulin, x100), C) Immunoreactivity for ACTH. (x100).

Table I: Hormonal Profile of the Patient

Laboratory Parameters	Values
Baseline Tests	
Baseline cortisol	27 ug/dl
Urinary cortisol	324 mcg/day
1 mg DST – Cortisol	14.1-15.8 ug/dl
2 mg-2 day DST - Cortisol	11.7-11.8 ug/dl
Adrenocorticotropin (ACTH)	27,8 pg/ml
After operation	
FSH	2.48 mIU/ml
LH	2.44 mIU/ml
Total testosterone	73.5 ng/dl
Prolactin	0.810 ng/ml
TSH	0.240 uIU/ml
Free T4	0.714 ng/dl

Cases of pituitary apoplexy have been reported during stimulation tests or hormone-replacement therapy. Bernstein et al. reported a case of pituitary apoplexy during triple bolus test (LH-RH, TRH and insulin) in 1984 (2). Rotman-Pikielny et al. have also reported pituitary apoplexy in a patient with Cushing's disease occurred during the CRH stimulation test (13). It has been suggested that glucocorticoids may increase catecholamines and these may lead to vasospasm and cause apoplexy. Tutanç et al. reported pituitary apoplexy occurred during levothyroxine treatment in a case of congenital hypothyroidism (14).

The exact mechanism of pituitary apoplexy is not clear. Nonetheless, several hypotheses have been put forward. These include rapid expansion of a tumor outgrowing its own blood supply (which leads to ischemic necrosis), growth of a tumor leading to compression of the pituitary portal blood supply against the diaphragma sella, and intrinsic vasculopathy or fragility of the blood vessels supporting a pituitary tumor. The clinicopathological consequences of pituitary apoplexy are caused by a rapid increase in size of the contents of the pituitary fossa and consequent elevation of intrasellar pressure (11).

ACTH-secreting macroadenomas are rare and apoplexy due to them has been reported very rarely (15). Rate of remissions in cases of ACTH-secreting macroadenomas without apoplexy is low; however, it is high in cases with apoplexy (12). Long-term follow-up is necessary in cases with apoplexy even in the presence of remission. Relapses have been reported even after seven years in cases of apoplexy (13). The start of the spontaneous regression of pituitary adenomas following apoplexy has not been clearly defined nor has the time it takes for complete resolution been clearly defined (2).

■ CONCLUSION

While apoplexy is reported after endocrine stimulation tests,

in our case the precipitating factor was not a stimulation but a suppression test. Association between suppression tests and apoplexy is not clearly defined, and this is the first report of pituitary apoplexy that developed during a suppression test. Physicians should be aware of this fact and consider pituitary apoplexy after suppression tests as well.

■ REFERENCES

- Badia X, Valassi E, Roset M, Webb SM: Disease-specific quality of life evaluation and its determinants in Cushing's syndrome: What have we learnt? *Pituitary* 17:187-195, 2014
- Bernstein M, Hegele RA, Gentili F, Brothers M, Holgate R, Sturtridge WC, Deck J: Pituitary apoplexy associated with a triple bolus test. Case report. *J Neurosurg* 61: 586-590, 1984
- Chan D, Rong TC, Dalan R: Cushing's disease presenting with pituitary apoplexy. *J Clin Neurosci* 19: 1586-1589, 2012
- Choudhry OJ, Choudhry AJ, Nunez EA, Eloy JA, Couldwell WT, Ciric JS, Liu JK: Pituitary tumor apoplexy in patients with Cushing's disease: Endocrinologic and visual outcomes after transsphenoidal surgery. *Pituitary* 15: 428-435, 2012
- Haboubi H, Azam I, Edavalath M, Redfern RM, Price DE, Stephens JW: Apoplexy in a corticotrophin-secreting pituitary macroadenoma: A case report and review of the literature. *Q J Med* 103:607-609, 2010
- Jackson DL, Van Gompel JJ: Rapid pituitary apoplexy regression: What is the time course of clot resolution? *Case Rep Radiol* 2015: 268974, 2015
- Johnston PC, Hamrahian AH, Weil RJ, Kennedy L: Pituitary tumor apoplexy. *J Clin Neurosci* 22: 939-944, 2015
- Kamiya Y, Jin-No Y, Tomita K, Suzuki T, Ban K, Sugiyama N, Mase M, Sakuma N, Kimura G: Recurrence of Cushing's disease after long-term remission due to pituitary apoplexy. *Endocr J* 47:793-797, 2000
- Rajasekaran S, Vanderpump M, Baldeweg S, Drake W, Reddy N, Lanyon M, Markey A, Plant G, Powell M, Sinha S, Wass J: UK guidelines for the management of pituitary apoplexy. *Clin Endocrinol* 74: 9-20, 2011
- Solomon AE, Tataranu L, Ciubotaru V, Gorgan M: Pituitary apoplexy: Clinical features, management and outcome. Clinical study and review of the literature. *Romanian Neurosurg* 22: 69-77, 2015
- Ranabir S, Baruah MP: Pituitary apoplexy. *Indian J Endocrinol Metab* 15: 188-196, 2011
- Rogg JM, Tung GA, Anderson G, Cortez S: Pituitary apoplexy: Early detection with diffusion-weighted MR imaging. *AJNR Am J Neuroradiol* 23: 1240-1245, 2002
- Rotman-Pikielny P, Patronas N, Papanicolaou DA: Pituitary apoplexy induced by corticotrophin-releasing hormone in a patient with Cushing's disease. *Clin Endocrinol (Oxf)* 58: 545-549, 2003
- Tutanc M, Altas M, Yengil E, Ustun I, Dolapcioglu KS, Balci A, Sefil F, Gokce C: Pituitary apoplexy due to thyroxine therapy in a patient with congenital hypothyroidism. *Acta Med Indones* 45: 306-311, 2013
- Watt A, Pobereskin L, Vaidya B: Pituitary apoplexy within a macroprolactinoma. *Nat Clin Pract Endocrinol Metab* 4: 635-641, 2008
- Zada G: Diagnosis and multimodality management of Cushing's Disease: A practical review. *Int J Endocrinol* 2013: 893781, 2013

