



DOI: 10.5137/1019-5149.JTN.16171-15.1

Received: 08.10.2015 / Accepted: 28.12.2015

Published Online: 06.05.2016

Original Investigation

Caudal Epidural Steroid Injections in Postlaminectomy Patients: Comparison of Ultrasonography and Fluoroscopy

Taylan AKKAYA¹, Derya OZKAN¹, Hayri KERTMEN², Zeki SEKERCİ²

¹Diskapi Yildirim Beyazit Training and Research Hospital, Department of Anaesthesiology, Pain Clinic, Ankara, Turkey

²Diskapi Yildirim Beyazit Training and Research Hospital, Department of Neurosurgery, Ankara, Turkey

ABSTRACT

AIM: To compare the results of ultrasound- and fluoroscopy-guided caudal epidural steroid injections in postlaminectomy patients.

MATERIAL and METHODS: Thirty postlaminectomy patients were randomly divided into two groups, Group I (n=15) received ultrasound-guided and Group II (n=15) received fluoroscopy-guided caudal epidural local anesthetic and steroid injection. Time of block for each patient was recorded. The patients' visual analogue scale (VAS), Oswestry Disability Index (ODI), and satisfaction with the therapy during the 3-month follow-up were evaluated.

RESULTS: The caudal block performed with both methods resulted in similar improvement in low back pain and functions. Time of block was shorter in Group I than in Group II (6.06 ±0.88 minutes versus 11.2±1.14 minutes).

CONCLUSION: Caudal epidural steroid injection is an effective analgesic method for postlaminectomy patients. Ultrasound-guided caudal block can be as effective as fluoroscopy-guided block and even more comfortable.

KEYWORDS: Caudal injection, Postlaminectomy pain, Steroid

■ INTRODUCTION

Low back pain (lumbago) is an important clinical problem in post-laminectomy patients. Unless treated early, it can attain a chronic neuropathic course, which requires a more complex therapy. For years, various epidural interventions (interlaminary, transforaminal, caudal) have been used for pain therapy in post-lumbar laminectomy (7). Caudal epidural blockade procures successful results in acute pain (in pediatric and adult inguinal and pelvic operations) as well as in chronic pain conditions (particularly in low back pain, pelvic pain, etc.) (13). For many years, caudal blockade had been administered utilizing the landmark technique. Since this technique does not provide adequate anesthesia and also causes some complications (dural perforation, hemorrhage, intraosseous injection, etc.), caudal blockade is currently performed under the guidance of fluoroscopy and ultrasound

imaging (USI). The use of these imaging methods increases the rate of success and decreases complications. Ultrasound is a good alternative to fluoroscopy, which has proven side effects (particularly radiation emission), is expensive and requires an additional technical team. Furthermore, in recent years, USI has been widely used in chronic pain cases as an effective and reliable imaging method (16).

In the present study, we compared the results of ultrasound- and fluoroscopy-guided caudal epidural steroid injections in lumbar postlaminectomy patients in terms of efficacy, ease of administration, patient satisfaction, and complications.

■ MATERIAL and METHODS

This study was a prospective, randomized, and controlled single-blinded study. The study protocol was approved by



Corresponding author: Derya OZKAN

E-mail: derya_z@yahoo.com

the Ethics Committee of the Ankara Dışkapı Yıldırım Beyazıt Training and Research Hospital (17 December 2012/No: 06/24).

The study included patients who had undergone L4-5 or L5-S1 hemilaminectomy within the last 1 year and who still had complaints of pain (axial, radicular, mixed type); the patients had an age range of between 20 and 50 and were in ASA 1-2. Patients with granulation tissue at the operation site determined by magnetic resonance imaging (MRI) controls were excluded from the study. The other criteria for exclusion were the following: more than one past operation, facet syndrome, previous instrumentation, spinal stenosis, anticoagulant use, advanced diabetes, and allergy to contrast substances and/or local anesthetics.

The patients were randomly allocated to one of the two groups according to the computer-generated random table. The patients in Group I (n=15) underwent US-guided and patients in Group II (n=15) fluoroscopy-guided caudal epidural blockade.

For caudal blockade, 2.5% bupivacaine and dexamethasone 8 mg were used. The dose of bupivacaine was calculated according to the formula: patient's height (m) x 10.

In the operation room, the patients underwent the standard monitorization (ECG, MAP, SpO₂) and vein access using a 20 G branule. Caudal blockade in the prone position was performed on patients in Group I. Under sterile conditions, the USI probe (Sonosite® M-Turbo Bothell WA, USA) (HFL 38X/13-6 MHz Transducer, Bothell WA, USA) was placed longitudinally on the vertebral axis to image the sacral hiatus. Following infiltration of the intervention site with 1-2 ml of 2% lidocaine, with a 20 G epidural needle (Thouhy needle), using the in-plain technique, the sacrococcygeal membrane was surpassed and the epidural area was reached. Upon observation of the needle tip in the epidural space, the local anesthetic was injected and its distribution was followed concurrently in the Doppler mode (Figure 1A, B).

Caudal blockade was performed on patients in Group II in the prone position. Under the C-arm fluoroscope, by first positioning them antero-posteriorly and then laterally, the sacrococcygeal junction was determined and the local anesthetic was injected into the epidural space with a 20 G epidural needle (Thouhy needle). Prior to the injection, the localization was confirmed by an epidurogram (Figure 2A, B).

The time of block in each patient was recorded. During the 3 hours following the intervention, an anesthesiologist who did not know of the groups, followed-up the patients in Phase II PACU in terms of hemodynamics, pain, motor block, sensory block, and possible complications (vasovagal reaction, facial flushing, headache, hematoma, and infection). The patients' satisfaction with the intervention was also recorded (yes-no). The patients were discharged on the same day of the intervention. They were invited for control visits in the post-interventional week 1 and at the 1st, 2nd, and 3rd months and were evaluated in terms of the VAS score (0, no pain; 10, the most severe pain), Oswestry Low Back Pain Disability Index (ODI) (5), and general satisfaction (0, no effect; 1, bad; 2, fairly; 3, good; 4, wonderful) scores. A second injection was planned for those patients with <50% regression in their complaints 3-4 weeks after the first intervention.

Statistics

In the pilot study performed at the beginning, the time of block was found 6±3 minutes in group I (n= 4) whereas 10±2 minutes in group II (n=4). Sample size were calculated on the basis of reduction in the time to performed the block with a error of 0.05 and 90% power was 22. Anticipating the dropout rate, 30 patients were included in the study.

Statistical analysis was carried out using the Statistical Package for Social Sciences (SPSS) version 17.0 software for Windows (SPSS Inc., Chicago, IL, United States). The values of continuous variables were given as mean (standard deviation) and nominal variables were expressed as the number of cases and percentage. Statistical analysis was performed

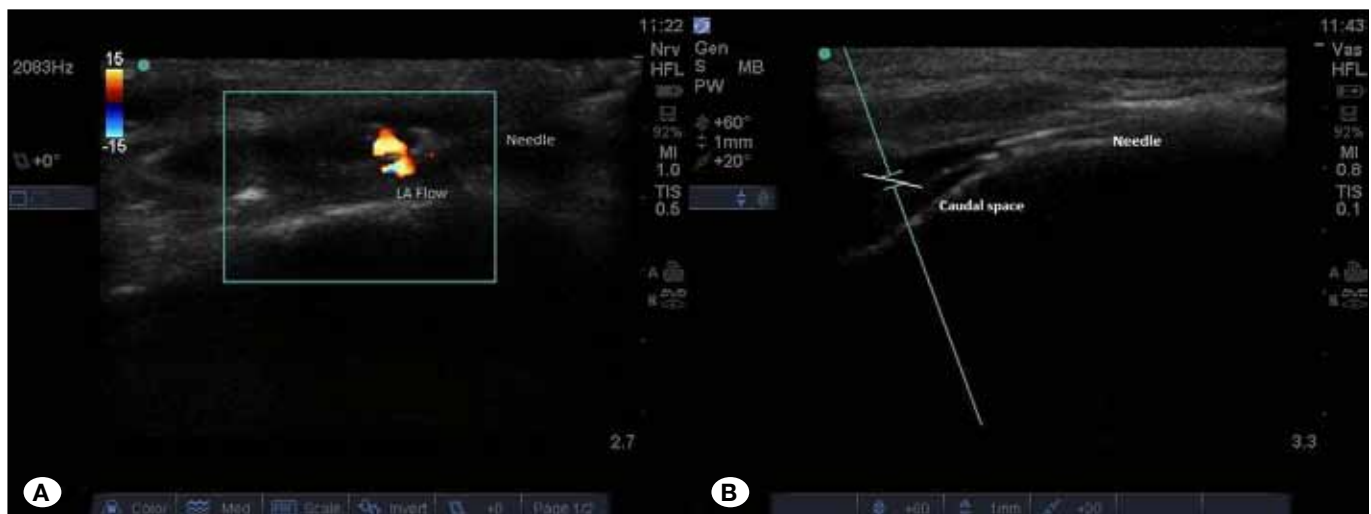

Figure 1: A,B) USI of the caudal space and distribution of the injected solution (HFL 38x/ 13-6 MHz Transducer Bothell WA, USA).

with t-test, for continuous variables, Mann-Whitney U test for nonparametric variables and χ^2 test for the categorical variables. A p value of <0.05 was considered statistically significant.

RESULTS

The study was completed by all of the patients (Figure 3). The patients had similar demographic characteristics ($p>0.05$)

(Table I). Because of continuation of pain at the 3rd-month follow-up period, 5 patients in Group I and 6 patients in Group II received a second caudal injection ($p>0.05$). The time at which the block was performed was 6.06 ± 0.88 minutes in Group I and 11.2 ± 1.14 minutes in Group II ($p<0.05$) (Table I). The patients had similar VAS scores ($p>0.05$) (Table II). When the ODI indices of the patients were compared, there was no statistically significant difference between Group I and Group II ($p>0.05$) (Table III).

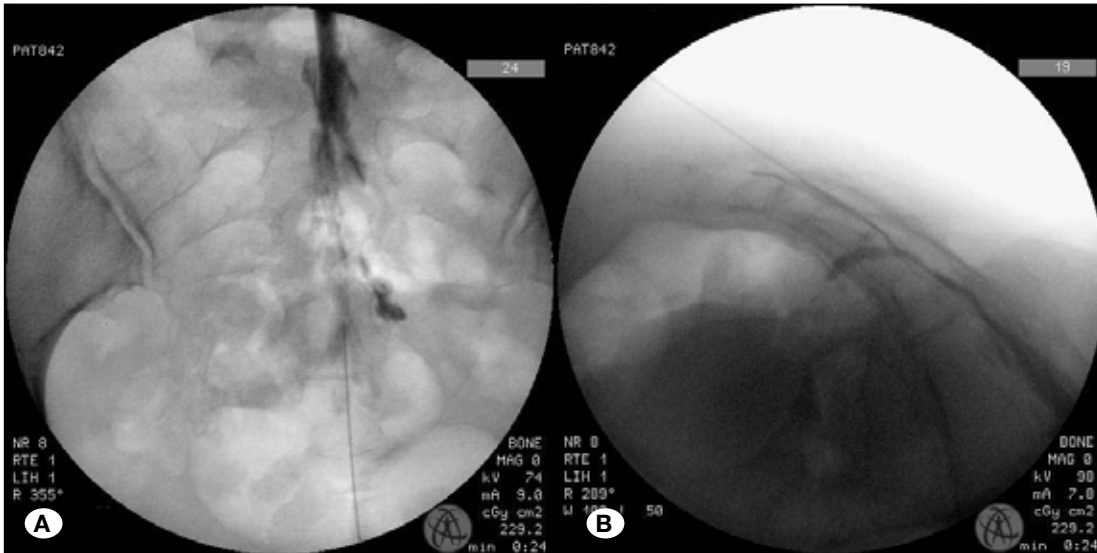


Figure 2A,B: Fluoroscopic imaging of the caudal space (Anteroposterior and lateral position).

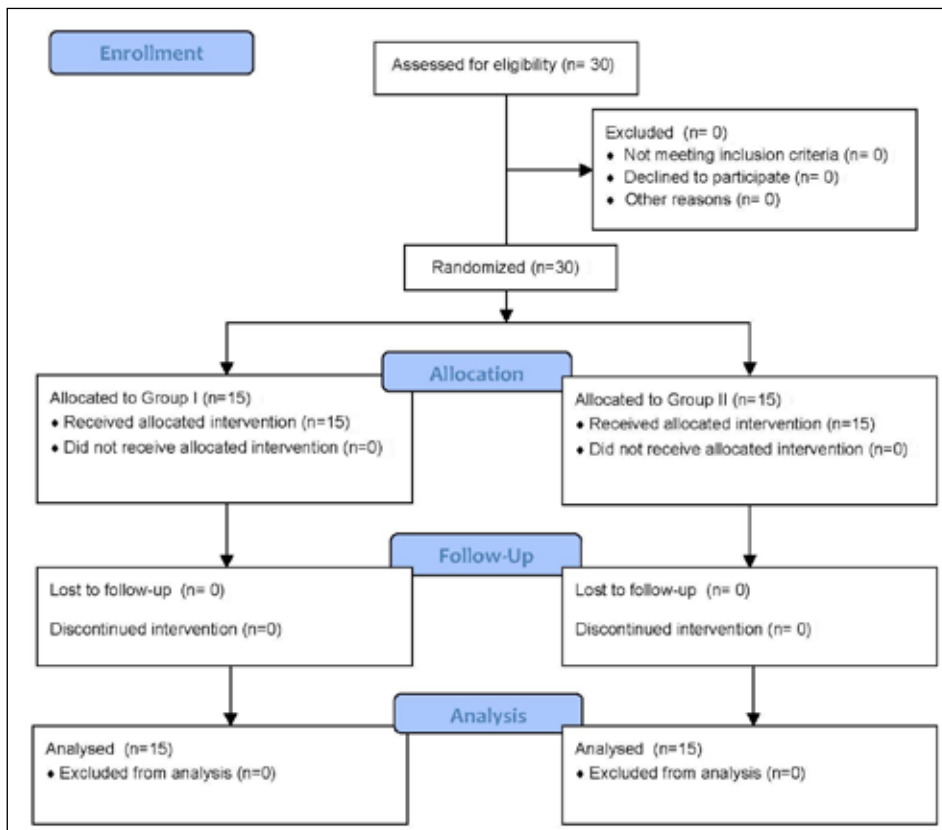


Figure 3: CONSORT diagram (Group I, US-guided; Group II, fluoroscopy-guided caudal block).

Table I: Demographic Details of the Patients [Values are Mean \pm SD or Number (Proportion)]

	Group I (n=15)	Group II (n=15)	p
Age, mean \pm SD, years	48.55 \pm 10.66	45.26 \pm 9.83	0.268
Male n (%)	6 (40%)	7 (46.7%)	
Female n (%)	9 (60%)	8 (53.3%)	
BMI, mean \pm SD, kg/m ²	25.48 \pm 2.74	24.88 \pm 3.92	0.642
Number of injections n (%)			
1	10 (60.7%)	9 (60%)	0.556
2	5 (33.3%)	6 (40%)	0.924
Target level n (%)			
L4-L5	11 (73%)	12 (80%)	
L5-S1	4 (27%)	3 (20%)	
Time to block (minutes)	6.06 \pm 0.88	11.2 \pm 1.14	0.0001 *

Table II: Pain Relief Characteristics of the Patients (VAS) (Values are Mean \pm SD)

	Group I (n=15)	Group II (n=15)	p
Base	6.33 \pm 1.23	6.2 \pm 0.94	0.725
1 st week	2.6 \pm 0.73	2.46 \pm 0.7	0.493
1 st month	2.8 \pm 0.56	2.53 \pm 0.51	0.186
2 nd month	3.00 \pm 0.67	3.11 \pm 0.78	0.257
3 rd month	4.39 \pm 0.95	4.52 \pm 0.87	0.455

Table III: ODI Indexes of the Patients (Values are Mean \pm SD)

	Group I (n=15)	Group II (n=15)	p
Base	54.14 \pm 10.19	52.33 \pm 22.74	0.835
1 st week	37.34 \pm 9.36	34.22 \pm 11.03	0.456
1 st month	26.19 \pm 5.41	28.16 \pm 6.12	0.355
2 nd month	23.25 \pm 5.33	21.41 \pm 4.33	0.288
3 rd month	33.78 \pm 10.08	35.12 \pm 11.45	0.955

Table IV: Patient Satisfaction Scores [Values are Number (Proportion)]

	Group I (n=15)	Group II (n=15)	p
0	-	-	
1	-	1 (6%)	0.566
2	1 (6%)	2 (14%)	0.453
3	6 (40%)	7 (47%)	0.266
4	8 (54%)	5 (33%)	0.763

Three patients in Group I and 9 patients in Group II expressed that they were dissatisfied with the procedure at the time of the intervention ($p < 0.001$).

With regard to the complications, in Group I, 2 patients had facial flushing and 1 patient had vasovagal reaction, and in Group II, 1 patient had facial flushing and 1 patient had transient headache. None of the patients had hemorrhage, infection or hematoma. There was no statistically significant difference in complications between the two groups ($p > 0.05$).

■ DISCUSSION

Caudal epidural steroid injection is important in the therapy of chronic pain following low back surgery. However, the application of this treatment with the classical landmark technique leads to various complications such as intraosseous injection, dural puncture, hemorrhage, and infection. Incorrect placement of the needle can occur in 14-56% of the cases who receive caudal epidural injections with no radiological guidance (2). In spite of fluoroscopy-guided correct needle localization and medication injection, emission of radiation is still a serious risk, both for the patient and interventionist. Use of USI in caudal epidural injections is a safe and fast modality to locate the sacral hiatus and to guide needle placement (9).

Fluoroscopy is of greater concern, as the average direct exposure dose per minute can range between 0.4-4.0 rad (15). Ionizing radiation specifically refers to radiation waves carrying enough energy to remove electrons from atoms or molecules, thereby generating excessive free radicals capable of inducing cellular damage (8). Cellular damage from ionizing radiation has been reported for the skin, eyes, gonads, and blood, with the most important long-term concern being cytogenetic and chromosomal damage resulting in increased risk of carcinogenesis (12). This damage increases with the energy of the radiation wave and with higher frequency of exposure, limiting the potential for cell recovery (15). In this study the average direct exposure dose of fluoroscopy was not assessed, but in fluoroscopy group, fluoroscopy was used least 2 minutes (6 shot). These doses also could be harmful hence morphological and functional damage has been observed in some cells dosed with as little as 0.001 rad (17).

Another important advantage of use of US in neural blockade is the morphometric measurements of the target area and the adjacent structures (20). A sacral canal diameter of less than 2 mm can result in increased failure rate of caudal blockade (14). On the other hand, color Doppler USI can visualize intravascular injections. Intravascular hemorrhage has been reported in 11-42% of the fluoroscopy-guided caudal epidural interventions (6). In the present study, there was no intravascular injection in either of the groups. Tsui et al. (18) have reported that US with its color Doppler feature can confirm whether the medication injected diffuses into the caudal area or not. The injection of fluid into the epidural space would result in turbulent flow, which would appear as a burst of color, while intrathecal injection would show an absence of a color flow Doppler signal.

The sacral canal and the sacral hiatus present a great number of anatomical variations. Advancing the needle more than 5 mm after passing the sacrococcygeal ligament may cause dural puncture (1). The needle tip should not be above the S-3 neural foramen as the dura may extend to that level. Caudal injections made with utmost attention particularly in post-spinal surgery patients may prevent dural tears. In such patients, the use of imaging methods during caudal epidural blockade gains more importance. Although the rate of success of caudal intervention in post-low back surgery is expected to be lower, in the present study, we had success rates of 100% in both groups. One important result of the present study was that the time at which the block was performed in the fluoroscopy group (12.7 ± 2.8 minutes) was longer than that in the US group (6.2 ± 0.3). This finding can be due to the fact that caudal anatomy can be visualized in more detail with USI. For example, Yoon et al. (19) have reported the success rate with US-guided caudal blockade as 94%. More relevant studies with larger patient populations are required.

Manchikanti et al. (10) have performed repeated fluoroscopy-guided caudal epidural blockade on their patients with post-lumbar surgery syndrome and reported the 1 year-follow up results. They have reported that the improvement in pain relief and functional status (ODI) is 53% in the group receiving only local anesthetic and 59% in the group receiving local anesthetic + steroid (10).

There have been many opinions on the mechanism of epidural steroid injections (4). Phospholipase A2, an inflammatory enzyme, is inhibited by corticosteroids. However, the main effect is due to the inhibition of arachidonic acid. In addition to their anti-inflammatory effects, steroids may inhibit pain via their ability to suppress ectopic discharges from injured nerve fibers and depress conduction in normal unmyelinated C fibers. The injection of local anesthetic can increase blood flow to ischemic nerve roots and, similar to steroids, it can suppress ectopic discharges from injured neurons and slow or halt nociceptive transmission. Moreover, the administration of saline, local anesthetic, or any non-steroid solution can exert an analgesic effect via the washout of inflammatory cytokines and the adhesiolysis of scar tissue.

In the present study, we tried to select patients who had undergone laminectomy at different levels, because Mohamed et al. (11) had reported similar results of ODI, analgesia, and patient satisfaction in caudal blockade patients with different levels of disc pathology (L4-5 and L5-S1).

Chen et al. (3) reported that out of 47 who had undergone US-guided caudal epidural injection, the intervention failed in 8 (15%). The reason for the failure was the closed sacral canal in 1, canal diameter of less than 1.5 mm in 5, and hemorrhage in 2 patients (3). In the present study, we found no difference in complications between the two groups. The patients in Group II felt more pain during the intervention than patients in Group I. This situation can be due to the fact that USI can readily demonstrate post-operative tissue changes during caudal intervention.

■ CONCLUSION

Caudal epidural steroid injections are safe and easy analgesia methods for post-laminectomy patients. Ultrasound-guided injections can be more advantageous for the patients in terms of patient satisfaction and duration of the intervention.

■ REFERENCES

1. Aggarwal A, Kaur H, Batra YK, Aggarwal AK, Rajeev S, Sahni D: Anatomic consideration of caudal epidural space: A cadaver study. *Clin Anat* 22: 730-737, 2009
2. Blanchais A, Le Goff B, Guillot P, Berthelot JM, Glemarec J, Maugars Y: Feasibility and safety of ultrasound guided caudal epidural injections. *Joint Bone Spine* 77: 440-444, 2010
3. Chen CP, Wong AM, Hsu CC, Tsai WC, Chang CN, Lin SC, Huang YC, Chang CH, Tang SF: Ultrasound as a screening tool for proceeding with caudal epidural injections. *Arch Phys Med Rehabil* 91:358-363, 2010
4. Cohen SP, Bicket MC, Jamison D, Wilkinson I, Rathmell JP: Epidural steroids. A comprehensive, evidence-based review. *Reg Anesth Pain Med* 38: 175-200, 2013
5. Fairbank JCT, Pynsent PB: The Oswestry disability index. *Spine* 25: 2940-2953, 2000
6. Fukazawa K, Matsuki Y, Ueno H, Hosokawa T, Hirose M: Risk factors related to accidental intravascular injection during caudal anaesthesia. *J Anesth* 28: 949-943, 2014
7. Hayek SM, Shah A: Nerve blocks for chronic pain. *Neurosurg Clin N Am* 25: 809-17, 2014
8. Herscovici D, Sanders RW: The effects, risks, and guidelines for radiation use in orthopaedic surgery. *Clin Orthop Relat Res.* 375:126-132, 2000
9. Klocke R, Jenkinson T, Glew D: Sonographically guided caudal epidural steroid injections. *J Ultrasound Med* 22: 1229-1232, 2003
10. Manchikanti L, Singh V, Cash KA, Pampati V, Datta S: Management of pain of post lumbar surgery syndrome: One year results of a randomized, double-blind, active controlled trial of fluoroscopic caudal epidural injections. *Pain Physician* 13: 509-521, 2010
11. Mohamed MM, Ahmed M, Chaudary M: Caudal epidural injection for L4-5 vs. L5-S1 disc prolapse. Is there any difference in the outcome? *J Spinal Disord Tech* 20:49-52, 2007
12. Mroz TE, Yamashita T, Davros WJ, Lieberman IH: Radiation exposure to the surgeon and the patient during kyphoplasty. *J Spinal Disord Tech* 21: 96-100, 2008
13. Najman IE, Frederico TN, Segurado AVR, Kimachi PP: Caudal epidural anesthesia: An anesthetic technique exclusive for pediatric use? Is it possible to use in adults? What is the role of the ultrasound in this context? *Rev Bras Anesthesiol* 61: 95-109, 2011.
14. Sekiguchi M, Yabuki K, Satoh K, Kikuchi S: An anatomic study of the sacral hiatus: A basis for the successful caudal epidural block. *Clin J Pain* 20: 51-54, 2004
15. Singer G: Occupational radiation exposure to the surgeon. *J Am Acad Orthop Surg* 13:69-76, 2005
16. Soneji N, Peng PW: Ultrasound-guided pain interventions-A review of techniques for peripheral nerves. *Korean J Pain* 26: 111-124, 2013
17. Tomei F, Papaleo B, Fantini S, Lavicoli S, Baccolo TP, Rosati MV: Vascular effects of occupational exposure to low-dose ionizing radiation. *Am J Ind Med* 30: 72-77, 1996
18. Tsui B, Leipoldt C, Desai S: Color flow Doppler ultrasonography can distinguish caudal epidural injection from intrathecal injection. *Anesth Analg* 116: 1376-1379, 2013
19. Yoon SJ, Sim KH, Kim SJ, Kim WS, Koh SB, Kim BJ: The feasibility of color Doppler ultrasonography for caudal epidural steroid injection. *Pain* 118: 210-214, 2005
20. Yucesoy C, Akkaya T, Ozel O, Cömert A, Tuccar E, Bedirli N, Unlü E, Hekimoğlu B, Gümüş H: Ultrasonographic evaluation and morphometric measurements of the suprascapular notch. *Surg Radiol Anat* 31: 409-414, 2009