



DOI: 10.5137/1019-5149.JTN.14570-15.1

Received: 28.03.2015 / Accepted: 06.07.2015

Published Online: 12.04.2016

## Case Report

# Management of Spinal Arteriovenous Fistulae with Intraarterial Indocyanine Green Angiography: A Case Report

Y.Sukru CAGLAR<sup>1</sup>, Mevci OZDEMIR<sup>2</sup>, Gokmen KAHILOGULLARI<sup>1</sup>, Melih BOZKURT<sup>1</sup>, Ayhan ATTAR<sup>1</sup>

<sup>1</sup>Ankara University, School of Medicine, Department of Neurosurgery, Ankara, Turkey

<sup>2</sup>Pamukkale University, School of Medicine, Department of Neurosurgery, Denizli, Turkey

### ABSTRACT

We describe herein intraoperative effectiveness of indocyanine green (ICG) video angiography to confirm dural arteriovenous fistulae. A 62-year-old man with a residual symptomatic dural arteriovenous fistula that was previously embolized at another institution is presented. On neurological examination, the motor strength in his both lower extremities was documented as grade 4 and the patella reflex was slightly increased. After verifying the presence of abnormal early venous drainage and retrograde flow with indocyanine green video angiography, the fistula was repaired. Postoperatively there was no additional neurologic deficit. Five days after the operation, the patient was discharged. Intraoperative ICG video angiography provides non-invasive and real-time information, reduction of spinal cord ischemic damage, rapid identification of feeding artery and confirmation of its complete disconnection during surgery, reduction of operative time, and improved outcome with no radiation hazard.

**KEYWORDS:** Videoangiography, Intraoperative angiography, Intraoperative imaging, Spinal dural arteriovenous fistula

### ■ INTRODUCTION

Spinal dural arteriovenous fistulae (SDAVFs) are the most common vascular lesions in the spinal cord (8,13,14). They can have good prognosis when treated sufficiently but treatment of these lesions is not easy every time. Intraoperative vascular imaging is a useful technique that can provide precise vascular anatomy. Various intraoperative imaging modalities have been proposed, such as color-coded Doppler sonography, spectral Doppler sonography, navigation, and intraoperative digital subtraction angiography (DSA) (1). Recently, microscope-integrated intravenous indocyanine green (ICG) angiography has been introduced as an adjunct for intracranial and spinal vascular lesions.

Here, we describe the efficacy of intra-arterial spinal ICG angiography in a spinal AVM and discuss its clinical implications.

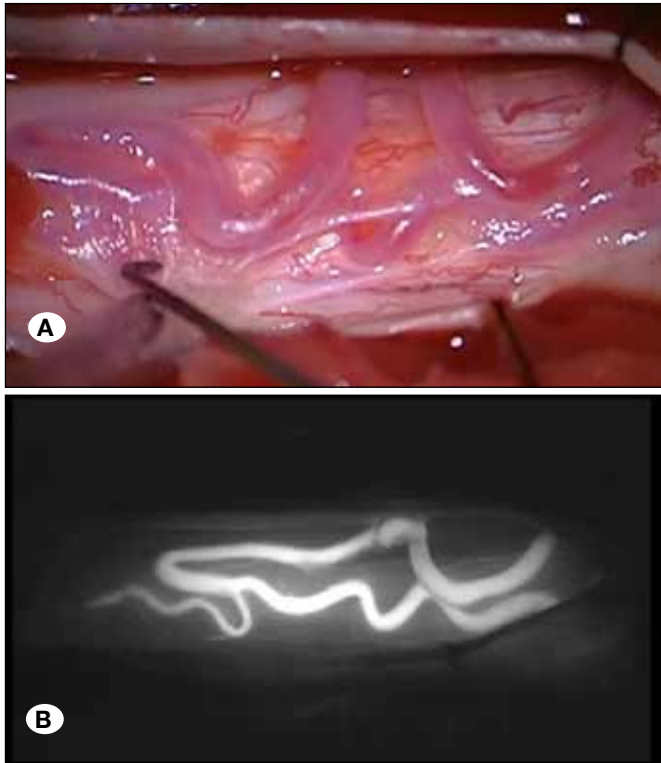
### ■ CASE REPORT

A 62-year-old man presented with a one-month history of sudden onset difficulty in walking and progressive bilateral lower extremity weakness. The neurological examination demonstrated a decrease in motor strength in his both lower extremities as grade 4 and the patella reflex was slightly increased. The patient had endovascular embolization in an outpatient clinic by the department of radiology. Approximately 9 months postoperatively, progressive worsening of his presenting symptoms was demonstrated. He was examined with a follow-up spinal magnetic resonance imaging (MRI), which showed spinal SDAVF at the level of Th11-12. Selective spinal catheter angiography revealed a right residual Th11-Th12 spinal SDAVF. Th11 and Th12 laminectomies were performed. After midline incision of the dura, abnormal arterialized veins were identified on the right side (Figure 1A). An operation microscope, adapted with an integrated fluorescence module (Carl Zeiss Co. Ltd, Oberkochen, Germany), was used. An attached video camera continuously

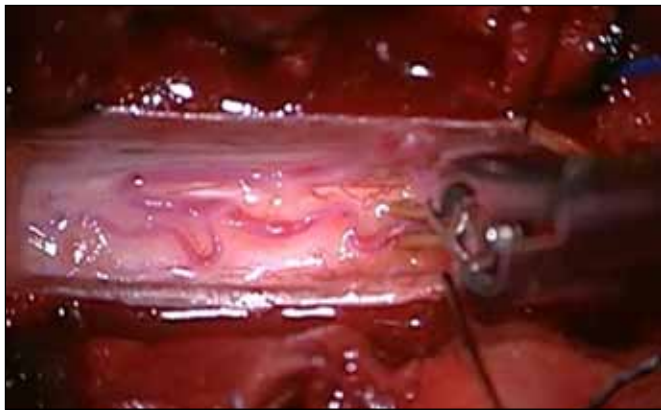
qr code

**Corresponding author:** Mevci OZDEMIR

**E-mail:** drmevci@hotmail.com

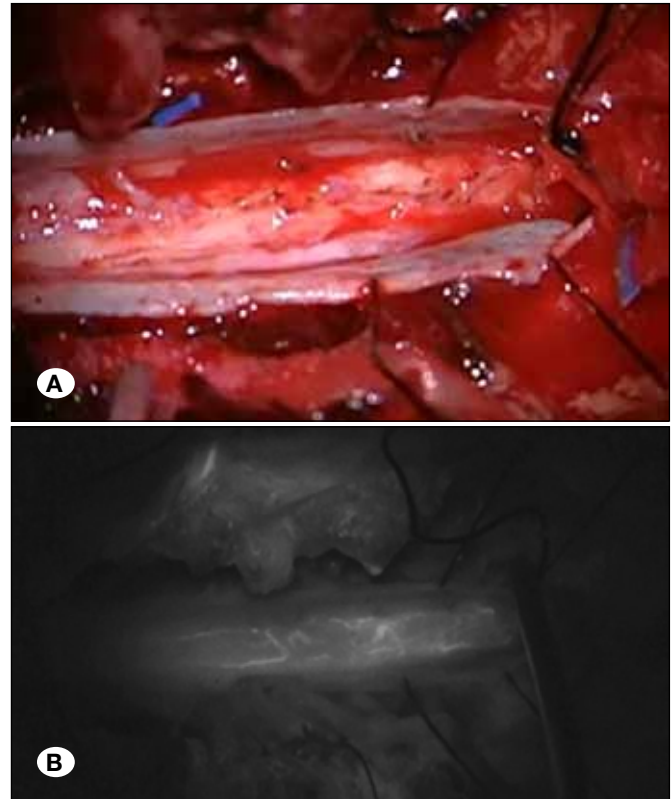


**Figure 1:** Magnified intraoperative (A) and ICG angiographic view (B) showing arterIALIZED medullary veins.



**Figure 2:** Intraoperative view of after clipping the feeding artery.

recorded high-resolution video angiograms. 25 mg ICG dye administered via intravenously through a peripheral venous line (Akorn, Buffalo Grove, Illinois, USA) and suspected vessels were confirmed using ICG video angiography (Figure 1B). After verifying the presence of abnormal early venous drainage and retrograde flow, a temporary clip was applied (Figure 2) and ICG video angiography was repeated to confirm repair of the fistula (Figure 3A, B). Postoperatively there was no additional neurologic deficit. The patient was discharged five day postoperatively.



**Figure 3:** Complete obliteration of the fistula, intraoperative (A) and ICG angiographic view (B).

## ■ DISCUSSION

Spinal DAVFs are common spinal vascular lesions that can lead to myelopathy if left untreated. If spinal DAVF is suspected because of clinical presentation, the MRI, magnetic resonance angiography (MRA) or computed tomography (CT) angiography findings can confirm the pathology, but, catheter-based digital subtraction angiography remains the gold standard (7). The primary goal of the treatment of spinal DAVFs is permanent and complete obliteration of the dilated dorsal spinal veins.

ICG angiography can be used to determine the dilated dorsal spinal veins correctly. ICG is a tricarbo-cyanine dye and in 1956, when the US Food and Drug Administration (FDA) approved ICG, a near infrared fluorescent dye, for the diagnosis of cardio-circulatory and liver function (2,5). The use of ICG video angiography for neurosurgical applications was introduced by Raabe et al. (9,10) using the fluorescent dye ICG to visualize blood flow through basal cerebral arteries and to confirm aneurysm clipping. ICG is administered intravenously through a peripheral or a central venous line. It is given at a standard dose of 0.2 to 0.5 mg/kg. ICG transforms into a near-infrared dye with a characteristic absorption and emission peak, and in the darkened operating room, the intravascular dye can then be visualized with the use of an operating microscope or with an external camcorder, each equipped with an additional fluorescent light source (wave length 700–850 nm) (11). The surgeon can then assess flow patterns in all vessels exposed

to the microscope light simply and rapidly. The technique has proved useful during routine aneurysm and bypass surgery as an independent form of angiography or as an adjunct to intra- or postoperative DSA.

Intraoperative ICG video angiography provides non-invasive and real-time information, reduces the chances of spinal cord ischemic damage, offers rapid identification of feeding artery and confirms complete disconnection during surgery, reduces operative time, and finally there is no radiation hazard, while it improves the patient's outcome (3). However this technique has its limitations. Limited area of observation, 10-20 minutes waiting till dissipation of ICG fluorescence, and repeat studies that are somewhat tedious and time-consuming, are the main disadvantages (6,11,12). Takami et al. summarized the utility of ICG video angiography into three categories: a) localization of normal spinal arteries and veins, b) assessment of posterior spinal venous circulation, and c) differentiation of feeding arteries, tumor, and draining veins. As well as giving such detailed information, the other important disadvantage of intraoperative ICG video angiography is that only exposes the surface vessels of spinal cord (15). ICG is excreted exclusively by the liver and is not reabsorbed from the intestine. Some adverse reactions have been reported after using ICG. The main side effects are nausea, pruritus, hypotension and arrhythmia (4).

## ■ CONCLUSION

Correct identification of arterialized veins during surgery is important. ICG video angiography enables us to evaluate the arterialized vein and confirm its disconnection so this technique can offer surgeons more confidence when treating these lesions during surgery.

## ■ REFERENCES

1. Akdemir H, Oktem S, Menku A, Tucer B, Tuğcu B, Günaldi O: Image-guided microneurosurgical management of small arteriovenous malformation: Role of neuronavigation and intraoperative Doppler sonography. *Minim Invasive Neurosurg* 50:163-169, 2007
2. Hanel RA, Nakaji P, Spetzler RF: Use of microscope-integrated near-infrared indocyanine green videoangiography in the surgical treatment of spinal dural arteriovenous fistulae. *Neurosurgery* 66:978-985, 2010
3. Hettige S, Walsh D: Indocyanine green video-angiography as an aid to surgical treatment of spinal dural arteriovenous fistulae. *Acta Neurochir* 152:533-536, 2010
4. Hope-Ross M, Yannuzzi LA, Gragoudas ES, Guyer DR, Slakter JS, Sorenson JA, Krupsky S, Orlock DA, Puliafito CA: Adverse reactions due to indocyanine green. *Ophthalmology* 101: 529-533, 1994
5. John T: Use of indocyanine green in deep lamellar endothelial keratoplasty. *J Cataract Refract Surg* 29:437-443, 2003
6. Killory BD, Nakaji P, Gonzales LF, Ponce FA, Wait SD, Spetzler RF: Prospective evaluation of surgical microscope-integrated intraoperative near-infrared indocyanine green angiography during cerebral arteriovenous malformation surgery. *Neurosurgery* 65:456-462, 2009
7. Killory BD, Nakaji P, Maughan PH, Wait SD, Spetzler RF: Evaluation of angiographically occult spinal dural arteriovenous fistulae with surgical microscope-integrated intraoperative near-infrared indocyanine green angiography: Report of 3 cases. *Neurosurgery* 68:781-787, 2011
8. Landsman MLJ, Kwant G, Mook GA, Zijlstra WG: Light absorbing properties, stability, and spectral stabilization of indocyanine green. *J Appl Physiol* 40:575-583, 1976
9. Raabe A, Beck J, Gerlach R, Zimmermann M, Seifert V: Near-infrared indocyanine green video angiography: A new method for intraoperative assessment of vascular flow. *Neurosurgery* 52:132-139, 2003
10. Raabe A, Nakaji P, Beck J, Kim LJ, Hsu FP, Kamerman JD, Seifert V, Spetzler RF: Prospective evaluation of surgical microscope-integrated intraoperative near-infrared indocyanine green videoangiography during aneurysm surgery. *J Neurosurg* 103:982-989, 2005
11. Schubert GA, Schmieder K, Rosenhagen MS, Thomé C: ICG videography facilitates interpretation of vascular supply and anatomical landmarks in intramedullary spinal lesions. *Spine* 36: 811-813, 2011
12. Schuette AJ, Cawley CM, Barrow DL: Indocyanine green videoangiography in the management of dural arteriovenous fistulae. *Neurosurgery* 67:658-662, 2010
13. Spetzler R, Detweiler P, Riina H, Porter R: Modified classification of spinal vascular lesions. *J Neurosurg* 96:145-156, 2002
14. Steinmetz MP, Chow MM, Krishnaney AA, Andrews-Hinders D, Benzel EC, Masaryk TJ, Mayberg MR, Rasmussen PA: Outcome after the treatment of spinal dural arteriovenous fistulae: A contemporary single-institution series and meta-analysis. *Neurosurgery* 55:77-87, 2004
15. Takami T, Yamagata T, Naito K, Arima H, Ohata K: Intraoperative assessment of spinal vascular flow in the surgery of spinal intramedullary tumors using indocyanine green videoangiography. *Surg Neurol Int* 4:135-140, 2013