



Review

Review of the Anatomy of the Distal Anterior Cerebral Artery and Its Anomalies

Karen CILLIERS, Benedict John PAGE

Stellenbosch University, Faculty of Medicine and Health Sciences, Department of Anatomy and Histology, Cape Town, Western Cape, South Africa

ABSTRACT

The anterior cerebral artery (ACA) varies considerably and this complicates the description of the normal anatomy. The segmentation of the ACA is mostly agreed on by different authors, although the relationship of the pericallosal and callosomarginal arteries (CmA) is not agreed upon. The two basic configurations of the ACA are determined by the presence or absence of the CmA.

The diameter, length and origin of the cortical branches have been measured and described by various authors and display great variability. Common anomalies of the ACA include the azygos, bihemispheric, and median anterior cerebral arteries.

A pilot study was done on 19 hemispheres to assess the variation of the branches of the ACA. The most common variations included absence and duplication. The inferior internal parietal artery and the CmA were most commonly absent and the paracentral lobule artery was the most frequently duplicated (36.8%). The inferior internal parietal artery originated from the posterior cerebral artery in 40.0% and this was the most unusual origin observed.

It is important to be aware of the possibility of variations since these variations can have serious clinical implications. The knowledge of these variations can be helpful to clinicians and neurosurgeons. The aim of this article is to review the anatomy and variations of the anterior cerebral artery, as described in the literature. This was also compared to the results from a pilot study.

KEYWORDS: Anterior cerebral artery, Variation, Anomaly, Anatomy, Description, Origin

ABBREVIATIONS: *ACA:* Anterior cerebral artery, *AcoA:* Anterior communicating artery, *AIFA:* Anterior internal frontal artery, *CmA:* Callosomarginal artery, *FpA:* Frontopolar artery, *IFA:* Internal frontal artery, *IfO:* Infraorbital artery, *IIPA:* Inferior internal parietal artery, *MIFA:* Middle internal frontal artery, *PIFA:* Posterior internal frontal artery, *PLA:* Paracentral lobule artery, *PrcA:* Pericallosal artery, *SIPA:* Superior internal parietal artery.

■ INTRODUCTION

The cerebral cortex is primarily supplied by the anterior, middle and posterior cerebral arteries. The anatomy of the anterior cerebral artery (ACA) varies considerably and this complicates the description of the ACA and its branches. The segmentation of the ACA is mostly described similarly by different authors, although the relationship of the pericallosal (PrcA) and callosomarginal arteries (CmA) is not agreed upon (78).

Segmentation

Various authors have used different terms to describe the segments of the ACA (36, 64, 68). It can be divided into proximal and distal segments, or pre- and postcommunicating segments. The pericallosal artery is distal to the A1 segment and consists of several segments that can be divided according to its relationship with the corpus callosum. The A2 segment (also referred to as the infracallosal section) runs vertically



Corresponding author: Karen CILLIERS

E-mail: 16173112@sun.ac.za

from the anterior communicating artery (AcoA) to the genu of the corpus callosum. The A3 segment (also referred to as the precallosal part) curves around the genu, and the A4 segment (also referred to as the supracallosal section) usually runs in the callosal sulcus and almost reaches the splenium (3, 58, 62). The A5 segment (cortical branches) varies considerably; it is therefore difficult to describe a standard arterial pattern (78). The two basic configurations of the ACA are determined by the presence or absence of the CmA (6, 58, 64). The different segments of the ACA are illustrated in Figure 1A, B.

A number of authors only describe three separate segments, namely the A1 segment (also referred to as the horizontal proximal segment or precommunicating part), the A2 segment (vertical proximal segment or postcommunicating part) and the A3 segment (the distal segments and cortical branches) (3). The A2 and A3 segments have collectively been referred to as the ascending (or vertical) segment and the A4 and the A5 segments as the horizontal segment (62, 64). The ACA have also been divided into a basal (from the origin to the rostrum of the corpus callosum) and a distal part (runs around genu and above corpus callosum) (62).

Several authors refer to the A1 segment as the anterior cerebral artery and the artery distal to the AcoA as the pericallosal artery (6, 36, 62, 64, 68). A few authors have also referred to the A1 and A2 segments as the anterior cerebral artery, and the artery distal to the origin of the callosomarginal artery, the pericallosal artery (62). Since the origin of the callosomarginal artery can vary, this terminology can be problematic (36). The CmA is also not always present and therefore it is preferable to classify the pericallosal artery as the segment distal to the AcoA (28, 62). The callosomarginal artery has been observed in 40.0% to 93.4% of specimens (6, 17, 28, 34, 44, 54, 62, 64, 65, 68, 69, 78). The variability of the absence or presence of

the CmA can be due to the different definitions used for this artery (65).

Cortical Branches

Callosomarginal Artery

The CmA can be seen as the largest branch of the pericallosal artery (6). The CmA has been defined as the artery that runs near the cingulate sulcus and gives off two or more cortical branches. This definition is problematic since there can occasionally be more than one artery that arises from the pericallosal artery, run in the cingulate sulcus and give rise to a number of cortical branches (78).

Ugur et al. (78) proposed a new classification system. The CmA was either defined as typical, atypical or absent. An atypical CmA was observed when there was only a very short artery coursing in the cingulate sulcus. Two symmetrical callosomarginal arteries can also be present in the same hemisphere (78). A typical CmA has a longer course compared to the two symmetrical atypical callosomarginal arteries and usually originates from the A3 segment (28, 62, 78). Ugur et al. (78) observed typical, atypical or absent CmA's in 49%, 34% and 17% respectively.

Infraorbital Artery

The infraorbital artery (IfO) normally originates from the A2 segment, the callosomarginal artery or as a common trunk with the frontopolar artery (36, 63, 68). In rare cases the IfO can originate from the A1 segment or from the internal frontal arteries. The infraorbital artery was present in 3.6% to 100% of cases (6, 17, 34, 62, 64, 68, 78). Duplication of the IfO have been observed in 6.0% (64), 39% (68) and 42% (78). Ugur et al. (78) observed three and four infraorbital arteries in 16% and 4%, respectively.

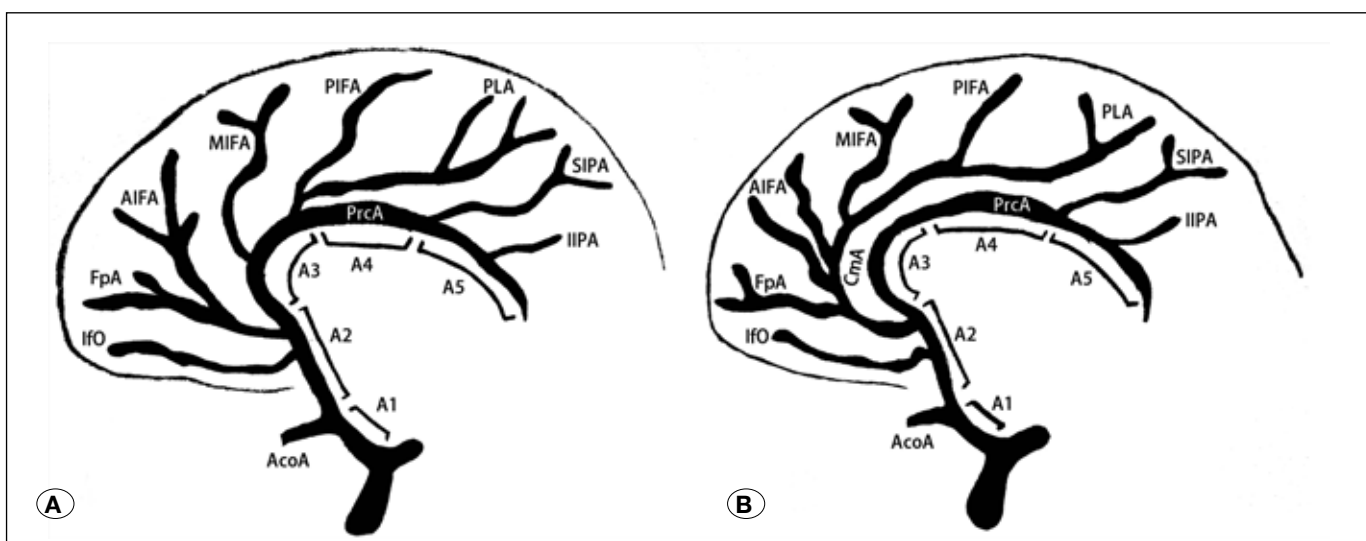


Figure 1: The different configurations of the anterior cerebral artery: **A)** CmA is absent, **B)** CmA is present. (AcoA) Anterior communicating artery; (AIFA) Anterior internal frontal artery; (CmA) Callosomarginal artery; (FpA) Frontopolar artery; (IfO) Infraorbital artery; (IIPA) Inferior internal parietal artery; (MIFA) Middle internal frontal artery; (PLA) Paracentral lobule artery; (PIFA) Posterior internal frontal artery; (PrcA) Pericallosal artery; and (SIPA) Superior internal parietal artery.

Frontopolar Artery

The frontopolar artery (FpA) usually arises from the A2 segment or callosomarginal artery (36, 68, 78). The FpA was present in 12.5% to 100% of cases (6, 17, 34, 62, 68, 78).

Internal Frontal Arteries

The anterior, middle and posterior internal frontal arteries usually arise separately or in groups of two from the CmA, although the internal frontal branches can occasionally originate from a common trunk, referred to as the internal frontal artery (IFA) (78). Ugur et al. (78) found that the internal frontal artery was present in 58% of cases. A number of studies (6, 17, 28, 34, 62, 68, 78) observed the anterior internal frontal artery (AIFA) in 33.9% to 100% of cases, the middle internal frontal artery (MIFA) in 64.3% to 100% of cases and the posterior internal frontal artery (PIFA) in 67.9% to 100% of cases.

Paracentral Lobule Artery

The paracentral lobule artery (PLA) can be viewed as the vessel with the most regular origin, course and area supplied, and was present in 53.6% to 100% of cases studied (6, 17, 34, 62, 68, 78).

Internal Parietal Arteries

The superior internal parietal artery normally originates from the A4 segment and runs to the precuneus (36). Ugur et al. (78) found that the superior internal parietal artery (SIPA) can also arise from the callosomarginal artery or the paracentral lobule artery. The inferior internal parietal artery (IIPA) originates from the A5 segment and runs to the lower third of the precuneus (36). A number of studies (17, 28, 34, 62, 68, 78) observed the SIPA in 78% to 100% of cases and the IIPA was present in 60% to 85% of cases observed.

Anomalies and Variations

The abnormalities of the distal ACA have been divided into three major groups (Figure 2A-D) namely; azygos ACA,

bihemispheric ACA and a median anterior cerebral artery. Other variations include complete absence of a pericallosal artery and four pericallosal vessels (25, 59). Ozaki et al. (59) described one case (0.7%) of duplication of the ACA bilaterally (four pericallosal vessels). Ladziński et al. (39) observed an extra ACA branch that originated from the internal carotid artery. Burbank and Morris (4) observed a left ACA arising from the right internal carotid artery and noted that only one other case has been observed in the literature.

Azygos Anterior Cerebral Artery

The azygos ACA (Figure 2A-D) is formed by the fusion of the two A2 segments and runs into the medial surface of the hemispheres and usually divides below the genu to supply both hemispheres (4, 6, 9-11, 17, 21, 25, 28, 32, 34, 36, 39, 42, 44, 49, 54, 57, 59, 60, 62, 63, 65, 69, 78). The azygos ACA can also be formed when the embryonic median artery persists (60).

The azygos ACA usually has little clinical significance (57) although this variation may be associated with other anomalies including agenesis of the corpus callosum, formation of arteriovenous malformations and ischemia (18, 24). Some authors state that aneurysms are frequently associated with an azygos ACA (9, 85), whereas others state that this association is extremely rare (35, 82). Since this artery supplies parts of both hemispheres, occlusion may result in a large ischemic area (9, 31, 57). The azygos ACA have been observed in 0.1% to 11.6% (1, 2, 12, 14, 17, 18, 20, 30, 43, 45, 51, 54, 67, 68, 74, 76, 78, 82, 83, 85) of cases studied.

The degree of fusion between the left and right ACA can vary from minor contact to a long single trunk (52, 70). Kapoor et al. (30) found that the trunk could be joined for 0.5cm to 4cm. When the arteries are connected for a shorter length, the variation can also be termed long fusion. Vasović (80) observed an azygos ACA that was fused for 3.3 mm and then divided into three arteries, the right and left A2 segments and a median anterior cerebral artery.

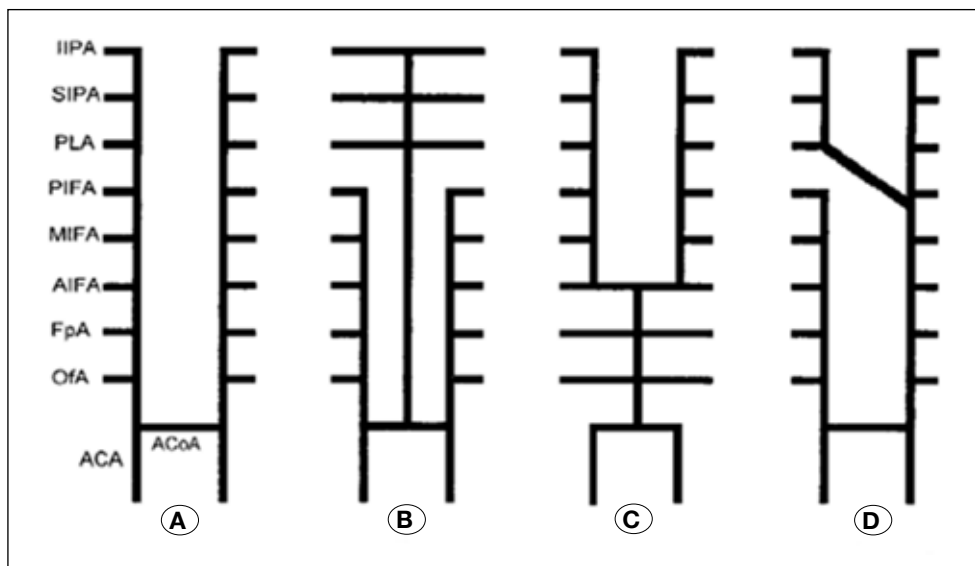


Figure 2: The different patterns of the anterior cerebral artery (68). **A)** Normal pattern, **B)** Median anterior cerebral artery, **C)** Azygos ACA, and **D)** Bihemispheric ACA.

Gunnal et al. (18) divided the azygos ACA into five subgroups (Figure 3). Type I is the classic or true azygos ACA while Type II consists of a shorter stem. In Type III there are two A2 segments, although one terminates early. In Type IV there are two A2 segments, although one terminates as the callosomarginal artery. Type V is the median anterior cerebral artery (18). Gunnal et al. (18) observed these five types in 2.7%, 1.8%, 3.6%, 2.7% and 0.9% respectively. The azygos ACA should not be confused with the bihemispheric ACA (classified as Type III and Type IV) (31, 73, 76).

The classic or true azygos anterior cerebral artery (Type I) can be described as an artery that does not divide into two distal ACA and gives rise to all cortical branches of both hemispheres. The azygos ACA usually divides close to the genu (Type II) into two pericallosal arteries to supply both hemispheres (18). This variation is more commonly observed compared to the true azygos ACA (21).

Bihemispheric Anterior Cerebral Artery

A bihemispheric ACA is defined when one A2 segment is hypoplastic (or terminates early) and the contralateral artery divides to supply both hemispheres (3, 11, 42, 57, 60, 62, 64). A bihemispheric ACA was present in 0.2% to 8.0% (20, 34, 62, 64, 65, 69,) of specimens cited in the literature.

Median Anterior Cerebral Artery

When the median ACA is observed, a third distal ACA is present and can branch to the distal medial surface of one or both hemispheres (11, 30, 36, 52, 60, 61, 68). The median ACA usually curves around the genu and ends at the level of the body of the corpus callosum (26). The cause of this variation is unknown although this artery can be the result of the persistent or patent development of the median artery of corpus callosum, possibly due to a hypoplastic ACA (11, 57, 61).

The median anterior cerebral artery usually originates from the AcoA (10, 13, 21, 46, 57, 61, 74). In the literature the median ACA originated from the AcoA in 87% (30), 90% (26) and 100% (28, 34, 37, 59, 65, 75, 83) of cases. The artery can additionally originate from the junction of the A1 and A2 segments in 10%

(26) and 13% (30) of cases. A median ACA was present in 1.0% to 35.0% (1, 8, 12, 13, 17, 26, 28, 30, 33, 34, 37, 38, 45, 47, 51, 53, 56, 59, 65, 67-69, 71, 74-76, 83, 85) of cases by previous authors. The average diameter of the median ACA has been measured to be 0.9 mm (75) and 1.28 mm (26).

Supreme Anterior Communicating Artery

This junction can also be termed the superior anterior communicating artery (23). There is an additional connection between the right and left A2 segments above the AcoA (18, 41). Laitinen and Snellman (41) observed this variation between the two pericallosal bifurcations. This variation has been observed in 20% (23) and 21.4% (41) of cases in the literature.

Fenestration

Fenestration occurs when the lumen of an artery is divided into two segments. It can also be referred to as partial duplication (2, 5, 16, 60, 72). Both segments have an endothelium and muscular layer although the adventitia can be shared (60). There are two types of fenestrations; small slit-like and large convex-like fenestrations. The small slit-like fenestration is the most common type (77).

These incomplete duplications are usually present in the vertebrobasilar region although it has been observed in the cerebral arteries (2, 19, 55, 60, 77). The weakness of the wall of the fenestration and hemodynamic stress at these locations can play a role in aneurysm formation (76).

Fenestrations of the ACA usually occur at the distal part of A1 segment (76) specifically, the distal half or two-thirds of the A1 segment (7, 48, 50). Most authors do not specify which part of the A1 segment the fenestration was observed. Ito et al. (22) stated that in all three cases the fenestration was located at the medial half of the A1 segment while Yamada et al. (84) also observed a fenestration at the middle part of the A1 segment. The cause is unknown although these fenestrations may be remnants of a plexiform anastomosis (57). Fenestrations of the ACA have been observed in the literature in 0.1% to 4.9% (30, 59, 66, 76, 79) of cases previously studied.

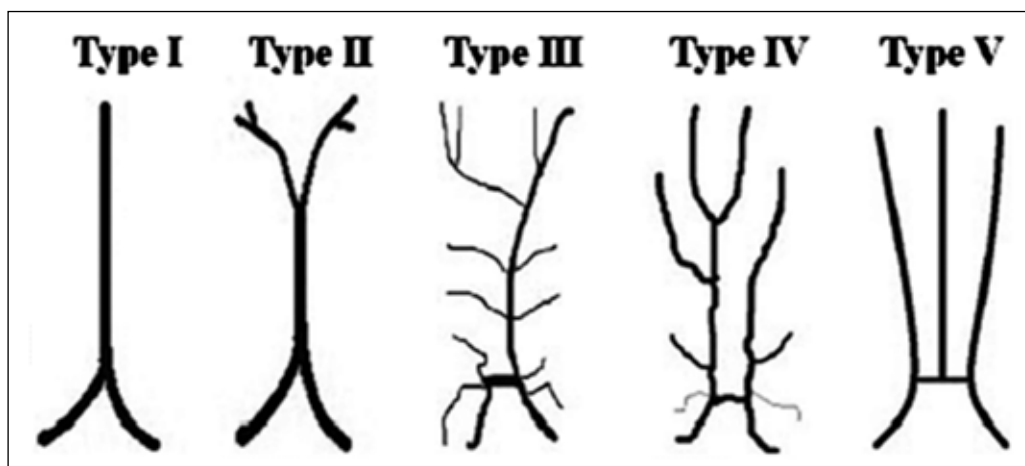


Figure 3: Four different types of an azygos anterior cerebral artery and the median anterior cerebral artery (18).

Very few authors specified if the fenestrations were small slit-like or large convex-like. Large convex-like fenestrations were observed in 1.0% and smaller slit-like fenestrations were observed in 0.2% of cases by Uchino et al. (76). Fenestrations of the ACA on both sides are extremely rare (22), although Friedlander and Oglivly (15) and Vucetić (81) reported bilateral fenestration of the A1 segment.

Pilot Study

A pilot study was done on 19 hemispheres to assess the anatomy of the ACA and its branches. The anterior cerebral arteries were injected with an isotonic saline solution to remove any blood or blood clots and were then injected with a coloured silicone. After perfusion the specimens were fixed in 10% buffered formaldehyde for at least two weeks. The external diameter was measured using a digital micrometre and the length was measured using string and a ruler.

The most common variations were complete absence of an artery and duplication. The infraorbital artery and the FpA

were absent in 42.1% and 47.4% of cases respectively. The anterior, middle and posterior internal frontal arteries were always present, although the AIFA and PIFA were duplicated in one case each. The MIFA was the most consistent artery, since it was always present and was never duplicated. The paracentral lobule artery was the most frequently duplicated and this was observed in 36.8% of cases. The superior and inferior internal parietal arteries were absent in 10.5% and 26.3% respectively and the IIPA was duplicated in one case. The callosomarginal artery and the IFA were observed in only 31.6% of cases in the pilot study. The callosomarginal artery and IFA were only present in the same hemisphere in one case.

The diameter, length and origin of the cortical branches of the ACA have been measured previously in the literature and this is depicted in Table I to Table IV. The data from the pilot study are tabulated in Table V. The diameters are measured at the origin of the cortical branch and the length is measured from the origin of the artery to the ACoA.

Knowledge of the course, length and curvature of the arteries is vital for treatment of pathologies. Variation of the length is important in neurosurgical procedures since a shorter trunk may play a role in aneurysm formation. Changes in vessel diameter could also indicate early signs of several pathological conditions (85).

The most notable origin was the IIPA originating from the posterior cerebral artery in 40.0% (Figure 4). This is a rare variation although Ladziński and Maliszewski (40) observed the inferior and superior internal parietal arteries arising from the posterior cerebral artery in one case (1.1%), and the IIPA arising from the posterior cerebral artery in five cases (5.3%).

The average diameters of the branches are similar to the results of Ugur et al. (78), Stefani et al. (68) and Perlmutter and Rhoton (62). The IIPA originated from the posterior cerebral artery in six cases, resulting in a much shorter length compared to when the IIPA originated from the anterior cerebral artery.

The differences of measured length between studies show that there might be marked difference between populations

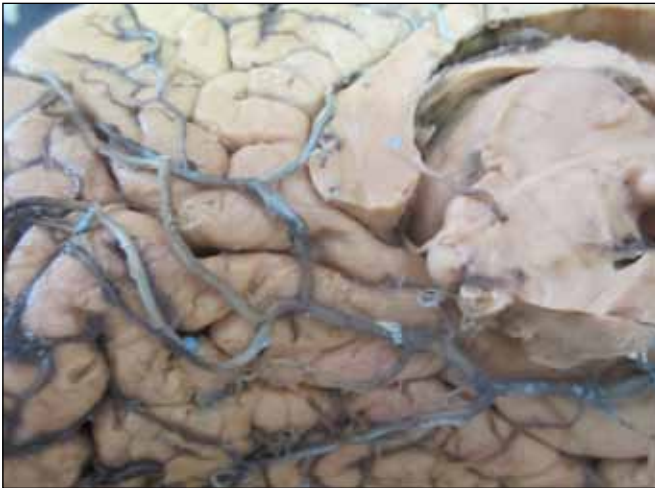


Figure 4: The inferior internal parietal artery originating from the posterior cerebral artery.

Table I: The Average Diameter (mm) at the Origin of the Arteries and the Average Length (mm)

Diameter	IfO	FpA	CmA	IFA	AIFA	MIFA	PIFA	PLA	SIPA	IIPA
Gomes et al. (1986)	0.9	1.2	1.8	-	1.0	1.0	1.0	1.1	0.8	0.7
Perlmutter and Rhoton (1978)	0.9	1.3	1.8	-	1.3	1.3	1.4	1.3	1.2	1.1
Stefani et al. (2000)	0.9	1.1	1.8	-	1.3	1.4	1.3	1.2	1.0	0.8
Ugur et al. (2006)	1.1	1.4	1.9	1.7	1.3	1.2	1.3	1.4	1.3	1.2
Cavalcanti et al. (2010)	0.6	0.9	1.5	-	1.1	1.1	1.0	1.0	1.1	-
Kedia et al. (2013)	0.2	0.5	1.1	-	0.4	0.4	0.3	0.3	0.3	0.2
Length	IfO	FpA	CmA	IFA	AIFA	MIFA	PIFA	PLA	SIPA	IIPA
Perlmutter and Rhoton (1978)	5.0	14.0	43.0	-	47.0	65.0	73.0	79.0	92.0	131.0
Stefani et al. (2000)	7.7	21.6	29.4	-	41.3	56.8	70.3	84.8	101.6	112.6
Avci et al. (2003)	6.0	14.6	-	-	-	-	-	-	-	-

Table II: The Origins of the Infraorbital, Frontopolar and Callosomarginal Arteries

	Authors	Present	A1	A2	A3	CmA	A4	Special
OfA	Ugur et al. (2006)	100%	1.0%	64.0%	-	-	-	-
	Perlmutter and Rhoton (1978)	100%	-	82.0%	-	-	-	Common trunk FpA: 18.0%
	Kedia et al. (2013)	100%	16.3%	83.3%	-	-	-	-
	Gomes et al. (1986)	100%	-	100%	-	-	-	-
	Kakou et al. (2000)	100%	17.0%	83.0%	-	-	-	-
	Avci et al. (2003)	100%	-	100%	-	-	-	-
FpA	Ugur et al. (2006)	98.0%	-	72.0%	-	9.0%	-	IFA: 14.0% AIFA: 3.0%
	Perlmutter and Rhoton (1978)	100%	-	90.0%	-	10.0%	-	-
	Kedia et al. (2013)	100%	-	40.0%	56.6%	3.3%	-	-
	Gomes et al. (1986)	100%	-	100%	-	-	-	-
	Kakou et al. (2000)	100%	17.0%	65.0%	9.0%	9.0%	-	-
	Avci et al. (2003)	100%	-	95.0%	5.0%	-	-	-
CmA	Ugur et al. (2006)	83.0%	-	18.0%	64.0%	-	12.0%	AcoA: 6.0%
	Perlmutter and Rhoton (1978)	82.0%	-	12.2%	73.2%	-	14.6%	-
	Kedia et al. (2013)	93.4%	-	10.0%	50.0%	-	40.0%	-
	Gomes et al. (1986)	91.6%	-	3.6%	90.9%	-	5.4%	-
	Kawashima et al. (2003)	91.0%	-	4.5%	91.0%	-	-	AcoA: 4.5%
	Cavalcanti et al. (2010)	93.3%	-	10.3%	55.2%	-	24.1%	AcoA: 10.3%

Table III: The Origins of the Anterior, Middle and Posterior Internal Frontal Arteries

	Authors	Present	A2	A3	CmA	IFA	A4	Special
AIFA	Ugur et al. (2006)	100%	4.0%	10.0%	18.0%	53.0%	-	FpA: 15.0%
	Perlmutter and Rhoton (1978)	86.0%	16.3%	55.8%	27.9%	-	-	-
	Kedia et al. (2013)	100%	13.3%	60.0%	26.6%	-	-	-
	Gomes et al. (1986)	96.6%	-	6.8%	84.4%	-	8.6%	-
	Kakou et al. (2000)	100%	-	65.0%	35.0%	-	-	-
MIFA	Ugur et al. (2006)	100%	-	21.0%	25.0%	50.0%	-	FpA: 4.0%
	Perlmutter and Rhoton (1978)	90.0%	2.2%	46.7%	46.7%	-	4.4%	-
	Kedia et al. (2013)	100%	-	43.3%	43.3%	-	13.4%	-
	Gomes et al. (1986)	98.3%	-	3.3%	77.9%	-	16.9%	A5: 1.6%
PIFA	Ugur et al. (2006)	100%	-	12.0%	48.0%	32.0%	2.0%	PLA: 6.0%
	Perlmutter and Rhoton (1978)	76.0%	-	31.6%	36.8%	-	31.6%	-
	Kedia et al. (2013)	100%	-	10.0%	80.0%	-	10.0%	-
	Gomes et al. (1986)	91.6%	-	-	56.3%	-	36.3%	A5: 7.2%

Table IV: The Origins of the Paracentral Lobule Artery and Internal Parietal Arteries (Superior and Inferior)

	Authors	Present	A3	CmA	A4	A5	Special:
PLA	Ugur et al. (2006)	100%	12.0%	66.0%	18.0%	-	Opposite A4: 2.0% IFA: 2.0%
	Perlmutter and Rhoton (1978)	90.0%	20.0%	28.9%	35.6%	15.6%	-
	Kedia et al. (2013)	100%	-	93.4%	6.6%	-	-
	Gomes et al. (1986)	98.3%	-	16.9%	33.8%	49.1%	-
	Kakou et al. (2000)	-	50.0%	50.0%	-	-	-
SIPA	Ugur et al. (2006)	88.0%	3.0%	30.0%	33.0%	24.0%	PLA:10.0%
	Perlmutter and Rhoton (1978)	78.0%	-	23.1%	12.8%	64.1%	-
	Kedia et al. (2013)	93.0%	-	-	80.0%	20.0%	-
	Gomes et al. (1986)	85.0%	-	-	-	100%	-
	Kakou et al. (2000)	100%	-	15.0%	35.0%	50.0%	-
IIPA	Ugur et al. (2006)	85.0%	-	-	10.0%	75.0%	SIPA:15.0%
	Perlmutter and Rhoton (1978)	64.0%	-	3.1%	16.6%	81.3%	-
	Kedia et al. (2013)	60.0%	-	-	-	100%	-
	Gomes et al. (1986)	60.0%	-	-	-	100%	-
	Kakou et al. (2000)	67.0%	-	-	-	100%	-

and therefore more studies need to be conducted on the length of these arteries. No triplication or other anomalies were observed in these specimens, which emphasizes the necessity for a large sample size to ensure that rare variation are observed.

■ CONCLUSION

The knowledge of the variations of the cerebral arteries is important to ensure that there are no complications during neurosurgery, surgical and endovascular interventions and it is essential for the treatment of cerebrovascular disease (6, 28, 64, 78). Aneurysms frequently occur at the branching of cerebral vessels and thus a thorough knowledge of the anatomy is important (4, 27, 29, 62). Information on the pattern of the cerebral arteries is important in interpretation of strokes and the obliteration of an arterial segment may cause unwanted or unexpected clinical consequences (21, 28).

■ ACKNOWLEDGEMENTS

The authors would like to thank Mr. RP Williams for technical assistance.

■ REFERENCES

- Avci E, Fossett D, Erdogan A, Egemen N, Attar A, Aslan M: Perforating branches of the anomalous anterior communicating complex. *Clin Neurol Neurosurg* 103(1):19-22, 2001
- Bharatha A, Aviv RI, White J, Fox AJ, Symons SP: Intracranial arterial fenestrations: Frequency on CT angiography and association with other vascular lesions. *Surg Radiol Anat* 30(5): 397-401, 2008
- Bradac GB: *Cerebral Angiography- Normal Anatomy and Vascular Pathology*. London: Springer, 2011: 47-56
- Burbank NS, Morris PP: Unique anomalous origin of the left anterior cerebral artery. *Am J Neuroradiol* 26(10): 2533-2535, 2005
- Canham PB, Finlay HM: Morphometry of medial gaps of human brain artery branches. *Stroke* 35(5):1153-1157, 2004
- Cavalcanti DD, Albuquerque FC, Silva BF, Spetzler RF, Preul MC: The anatomy of the callosomarginal artery: Applications to microsurgery and endovascular surgery. *Neurosurgery* 66(3):602-610, 2010
- Choudhary KA: Fenestrated anterior cerebral artery. *Br J Neurosurg* 16(5):525-529, 2002
- Cilliers K, Vorster W, Page BJ: The anatomical variation of the circle of Willis in a cadaver cohort representing the population dynamics of the Western Cape (Unpublished research report), Stellenbosch: Stellenbosch University, 2013
- Cinnamon J, Zito J, Chalif DJ, Gorey MT, Black KS, Scuderi DM, Hyman RA: Aneurysm of the azygos pericallosal artery: Diagnosis by MR imaging and MR angiography. *Am J Neuroradiol* 13(1): 280-282, 1992
- Critchley M: Syndromes of the anterior cerebral artery. *Proc R Soc Med* 23(5):630-632, 1930
- Dimmick SJ, Faulder KC: Normal variants of the cerebral circulation at multidetector CT angiography. *Radiographics* 29(4): 1027-1043, 2009

12. Dunker RO, Harris AB: Surgical anatomy of the proximal anterior cerebral artery. *J Neurosurg* 44(3):359-367, 1976
13. Fawcett E, Blachford JV: The circle of Willis: An examination of 700 specimens. *J Anat Physiol* 40:63-70, 1905
14. Fisher CM: The circle of Willis: Anatomical variations. *Vasc Dis* 2: 99-105, 1965
15. Friedlander RM, Oglivly CS: Aneurysmal subarachnoid hemorrhage in a patient with bilateral A1 fenestrations associated with an azygos anterior cerebral artery. Case report and literature review. *J Neurosurg* 84(4): 681-684, 1996
16. Gailloud P, Albayram S, Fasel JH, Beauchamp NJ, Murphy KJ: Angiographic and embryologic considerations in five cases of middle cerebral artery fenestration. *Am J Neuroradiol* 23(4):585-587, 2002
17. Gomes FB, Dujovny M, Umansky F, Berman SK, Diaz FG, Ausman JI, Mirchandani HG, Ray WJ: Microanatomy of the anterior cerebral artery. *Surg Neurol* 26(2):129-141, 1986
18. Gunnal SA, Wabale RN, Farooqui MS: Variations of anterior cerebral artery in human cadavers. *Neurology Asia* 18(3):249-259, 2013
19. Hattori T, Kobayashi, H: Fenestration of the supraclinoid internal carotid artery associated with carotid bifurcation aneurysm. *Surg Neurol* 37(4):284-288, 1992
20. Huber P, Braun J, Hirschmann D, Agyeman JF: Incidence of berry aneurysms of the unpaired pericallosal artery: Angiographic study. *Neuroradiology* 19(3):143-147, 1980
21. Hussain Z, Corkill RA, Kuker W, Byrne JV: Distal aneurysms of the unpaired ACA: Embryologic and therapeutic aspects. *Neuroradiology* 47(3):209-214, 2005
22. Ito J, Washiyama K, Kim CH, Ibuchi Y: Fenestration of the anterior cerebral artery. *Neuroradiology* 21(5):277-280, 1981
23. Izci Y, Agrawal B, Ateş O, Başkaya MK: Superficial vascular anatomy of the medial prefrontal cortex: An anatomical study. *Surg Neurol* 72(4): 383-388, 2009
24. Jennings S, Haider A: Case report: The clinical significance of an azygos anterior cerebral artery. *International Journal of Anatomical Variations* 4:185-187, 2011
25. Jinkins JRL: Atlas of Neuroradiologic Embryology, Anatomy, and Variants. Lippincott Williams and Wilkins, 2000
26. Kahilogullari G, Comert A, Arslan M, Esmer AF, Tuccar E, Elhan A, Tubbs RS, Ugur HC: Callosal branches of the anterior cerebral artery: An anatomical report. *Clin Anat* 21(5):383-388, 2008
27. Kahilogullari G, Ugur HC, Comert A, Tekdemir I, Kanpolat Y: The branching pattern of the middle cerebral artery: Is the intermediate trunk real or not? An anatomical study correlating with simple angiography Laboratory investigation. *J Neurosurg* 116(5):1024-1034, 2012
28. Kakou M, Destrieux C, Velut S: Microanatomy of the pericallosal arterial complex. *J Neurosurg* 93:667-675, 2000
29. Kaplan HA: The lateral perforating branches of the anterior and middle cerebral arteries. *J Neurosurg* 23(3):305-310, 1965
30. Kapoor K, Singh B, Dewan LI: Variations in the configuration of the circle of Willis. *Anat Sci Int* 83(2):96-106, 2008
31. Kathuria S, Gregg L, Chen J, Gandhi D: Normal cerebral arterial development and variations. *Semin Ultrasound CT MR* 32(3): 242-251, 2011
32. Katz RW, Horoupian DS, Zingesser L: Aneurysm of azygos anterior cerebral artery. A case report. *J Neurosurg* 48(5):804-808, 1978
33. Kayembe KN, Sasahara M, Hazama F: Cerebral aneurysms and variations in the circle of Willis. *Stroke* 15(5):846-850, 1984
34. Kedia S, Daisy S, Mukherjee KK, Salunke P, Srinivasa R, Narain MS: Microsurgical anatomy of the anterior cerebral artery in Indian cadavers. *Neurol India* 61(2):117-121, 2013
35. Kondo A, Koyama T, Ishikawa J, Iwaki K, Yamasaki T: Ruptured aneurysm of an azygos anterior cerebral artery. *Neuroradiology* 17(4):227-229, 1979
36. Krayenbuhl H, Yasargil MG, Huber P: Cerebral Angiography. Thieme Medical Publishers, 1982: 79-93
37. Kulenović A, Dilberović F, Ovcina F: Variation in the flow and branching of the anterior and middle cerebral arteries. *Med Arh* 57(1):3-5, 2003 (Abstract)
38. Kwak R, Niizuma H, Hatanaka M, Suzuki J: Anterior communicating artery aneurysms with associated anomalies. *J Neurosurg* 52(2): 162-164, 1980
39. Ladziński P, Maliszewski M, Majchrzak H: The accessory anterior cerebral artery: Case report and anatomic analysis of vascular anomaly. *Surg Neurol* 48(2):171-174, 1997
40. Ladziński P, Maliszewski M: Variability of the division of the cortical branches of the posterior cerebral artery. *Anat Rec A Discov Mol Cell Evol Biol* 282(1):74-82, 2005
41. Laitinen L, Snellman A: Aneurysms of the pericallosal artery. A study of 14 cases verified angiographically and treated mainly by direct surgical attack. *J Neurosurg* 17:447-458, 1960
42. Lehecka M, Dashti R, Hernesniemi J, Niemelä M, Koivisto T, Ronkainen A, Rinne J, Jääskeläinen J: Microneurosurgical management of aneurysms at the A2 segment of anterior cerebral artery (proximal pericallosal artery) and its frontobasal branches. *Surg Neurol* 70(3):232-246, 2008
43. Lemay M, Gooding CA: The clinical significance of the azygos anterior cerebral artery (ACA). *Am J Roentgenol Radium Ther Nucl Med* 98:602-610, 1966
44. Lemos VPJ: Frequency of the callosomarginal artery and proposal of a hypothesis with regard to its phylogenetic significance. *Arq Neuropsiquiatr* 42(4): 335-340, 1984
45. Macchi C, Catini C, Federico C, Gulisano M, Pacini P, Cecchi F, Corcos L, Brizzi E: Magnetic resonance angiographic evaluation of circulus arteriosus cerebri (circle of Willis): A morphologic study in 100 human healthy subjects. *Ital J Anat Embryol* 101(2):115-123, 1996 (Abstract)
46. Makowicz G, Poniatowska R, Lusawa M: Variants of cerebral arteries - anterior circulation. *Pol J Radiol* 78(3):42-47, 2013
47. Marinković S, Milisavljević M, Marinković Z: Branches of the anterior communicating artery. Microsurgical anatomy. *Acta Neurochir (Wien)* 106(1-2):78-85, 1990 (Abstract)
48. Matsumura M, Nojiri K: Ruptured anterior communicating artery aneurysms associated with fenestration of the anterior cerebral artery. *Surg Neurol* 22(4):371-376, 1984
49. Milenković Z, Vucetić R, Puzić M: Asymmetry and anomalies of the circle of Willis in fetal brain. Microsurgical study and functional remarks. *Surg Neurol* 24(5):563-570, 1985
50. Minakawa T, Kawamata M, Hayano M, Kawakami K: Aneurysms associated with fenestrated anterior cerebral arteries. Report of four cases and review of the literature. *Surg Neurol* 24(3):284-288, 1985
51. Nathal E, Yasui N, Sampei T, Suzuki A: Intraoperative anatomical studies in patients with aneurysms of the anterior communicating artery complex. *J Neurosurg* 76(4):629-634, 1992

52. Niederberger E, Gauvrit JY, Morandi X, Carsin-Nicol B, Gauthier T, Ferré JC: Anatomic variants of the anterior part of the cerebral arterial circle at multidetector computed tomography angiography. *J Neuroradiol* 37(3):139-147, 2010
53. Nordon DG, Rodrigues OFJ: Variations in the brain circulation – the circle of Willis. *J Morphol Sci* 29(4):243-247, 2012
54. Nowinski WL, Thirunavuukarasuu A, Volkau I, Marchenko Y, Aminah B, Puspitasari F, Runge VM: A three-dimensional interactive atlas of cerebral arterial variants. *Neuroinformatics* 7(4):255-264, 2009
55. Nussbaum ES, Defillo A, Janjua TM, Nussbaum LA: Fenestration of the middle cerebral artery with an associated ruptured aneurysm. *J Clin Neurosci* 16(6):845-847, 2009
56. Ogawa A, Suzuki M, Sakurai Y, Yoshimoto T: Vascular anomalies associated with aneurysms of the anterior communicating artery: Microsurgical observations. *J Neurosurg* 72(5):706-709, 1990
57. Okahara M, Kiyosue H, Mori H, Tanoue S, Sainou M, Nagatomi H: Anatomic variations of the cerebral arteries and their embryology: A pictorial review. *Eur Radiol* 12(10):2548-2561, 2002
58. Osborn AG, Jacobs JM: *Diagnostic Cerebral Angiography*. 2nd ed. Lippincott Williams and Wilkins, 1999: 117-133
59. Ozaki T, Handa H, Tomimoto K, Hazama F: Anatomical variations of the arterial system of the base of the brain. *Arch Jpn Chir* 46: 3-17, 1977
60. Parmar H, Sitoh YY, Hui F: Normal variants of the intracranial circulation demonstrated by MR angiography at 3T. *Eur J Radiol* 56(2):220-228, 2005
61. Pekcevik Y, Hasbay E, Oncel D: Colloid cyst of the third ventricle associated with anterior cerebral artery trifurcation and agenesis of the corpus callosum: Findings on MRI and CT angiography. *Pediatr Radiol* 42(9):1130-1133, 2012
62. Perlmutter D, Rhoton AL: Microsurgical anatomy of the distal anterior cerebral artery. *J Neurosurg* 49:204-228, 1978
63. Ramos A, Chaddad-Neto F, Joaquim AF, Campos-Filho JM, Mattos JP, Ribas GC, Oliveira ED: The microsurgical anatomy of the gyrus rectus area and its neurosurgical implications. *Arq Neuropsiquiatr* 67(1):90-95, 2009
64. Ring BA, Waddington MM: Roentgenographic anatomy of the pericallosal arteries. *Am J Roentgenol Radium Ther Nucl Med* 104:109-118, 1968
65. Saidi H, Kitunguu PK, Ogeng'O JA: Variant anatomy of the anterior cerebral artery in adult brains. *Afr J Neurol Sci* 27(1):97-105, 2008
66. Sanders WP, Sorek PA, Mehta BA: Fenestration of intracranial arteries with special attention to associated aneurysms and other anomalies. *Am J Neuroradiol* 14(3):675-680, 1993 (Abstract)
67. Serizawa T, Saeki N, Yamaura A: Microsurgical anatomy and clinical significance of the anterior communicating artery and its perforating branches. *Neurosurgery* 40(6):1211-1216, 1997
68. Stefani MA, Schneider FL, Marrone ACH, Severino AG, Jackowski AP, Wallace MC: Anatomic variations of anterior cerebral artery cortical branches. *Clin Anat* 13:231-236, 2000
69. Stefani MA, Schneider FL, Marrone ACH, Severino AG: Influence of the gender on cerebral vascular diameters observed during the magnetic resonance angiographic examination of Willis circle. *Braz Arch Biol Technol* 56(1):45-52, 2013
70. Szdzyt D, Lehmann R, Nickel B: Common trunk of the anterior cerebral arteries. *Neuroradiology* 4(1):51-56, 1972
71. Tao X, Yu XJ, Bhattarai B, Li TH, Jin H, Wei GW, Ming JS, Ren W, Jiong C: Microsurgical anatomy of the anterior communicating artery complex in adult Chinese heads. *Surg Neurol* 65(2):155-161, 2006
72. Teal JS, Rumbaugh CL, Bergeron RT, Segall HD: Angiographic demonstration of fenestrations of the intradural intracranial arteries. *Radiology* 106(1):123-126, 1973
73. Topsakal C, Ozveren MF, Erol FS, Cihangiroglu M, Cetin H: Giant aneurysm of the azygos pericallosal artery: Case report and review of the literature. *Surg Neurol* 60(6):524-533, 2003
74. Tulleken CA: A study of the anatomy of the anterior communicating artery with the aid of the operating microscope. *Clin Neurol Neurosurg* 80(3):169-173, 1978
75. Türe U, Yaşargil MG, Krisht AF: The arteries of the corpus callosum: A microsurgical anatomic study. *Neurosurgery* 39(6): 1075-1084, 1996
76. Uchino A, Nomiyama K, Takase Y, Kudo S: Anterior cerebral artery variations detected by MR angiography. *Neuroradiology* 48(9): 647-652, 2006
77. Uchino A, Takase Y, Nomiyama K, Egashira R, Kudo S: Fenestration of the middle cerebral artery detected by MR angiography. *Magn Reson Med Sci* 5(1):51-55, 2006
78. Ugur HC, Kahilogullari G, Esmer AF, Combet A, Kanpolat Y: A neurosurgical view of anatomical variations of the distal anterior cerebral artery: An anatomical study. *J Neurosurg* 104:1-7, 2006
79. Vasočić L, Trandafilović M, Vlajković S, Jovanović I, Ugrenović S: Anterior cerebral–anterior communicating complex in the postnatal period: From a fenestration to the multiplication of arteries. *Medicine and Biology* 16(1):1-11, 2014
80. Vasočić LP: Fetal azygos pericallosal artery. *Clin Anat* 19(4): 327-331, 2006
81. Vucetić RR: Segmental duplication of the fetal anterior cerebral artery. *J Anat* 192(3):431-434, 1998
82. Wan-Yin S, Ming-Hua L, Bin-Xian G, Yong-Dong L, Hua-Qiao T: Azygous anterior cerebral artery and associated aneurysms: Detection and identification using 3-dimensional time-of-flight magnetic resonance angiography. *J Neuroimaging* 24(1):18-22, 2014
83. Windle BC: The arteries forming the Circle of Willis. *J Anat Physiol* 22(2):289-293, 1888
84. Yamada T, Inagawa T, Takeda T: Ruptured aneurysm at the anterior cerebral artery fenestration. Case report. *J Neurosurg* 57(6): 826-828, 1982
85. Zurada A, Gielecki J, Tubbs RS, Loukas M, Cohen-Gadol AA, Chlebiej M, Maksymowicz W, Nowak D, Zawilński J, Michalak M: Three-dimensional morphometry of the A2 segment of the anterior cerebral artery with neurosurgical relevance. *Clin Anat* 23(7):759-769, 2010