



DOI: 10.5137/1019-5149.JTN.13345-14.0

Received: 06.11.2014 / Accepted: 16.12.2014

Published Online: 24.02.2016

## Case Report

# Gamma Knife Radiosurgery for Tumors of the Endolymphatic Sac

Ayşegül ÜÇÜNCÜ KEFELİ<sup>1</sup>, Meltem YILMAZ<sup>2</sup>, Meriç ŞENGÖZ<sup>3</sup>, Selçuk PEKER<sup>4</sup>

<sup>1</sup>Marmara University, School of Medicine, Department of Radiation Oncology, Istanbul, Turkey

<sup>2</sup>Acıbadem Kozyatağı Hospital, Department of Radiation Oncology, Istanbul, Turkey

<sup>3</sup>Acıbadem University, School of Medicine, Department of Radiation Oncology, Istanbul, Turkey

<sup>4</sup>Acıbadem University, School of Medicine, Department of Neurosurgery, Istanbul, Turkey

## ABSTRACT

Tumors of the endolymphatic sac are locally invasive temporal bone neoplasms. Radical surgical excision is the treatment of choice; however, the aggressive nature of these tumors can make total excision impossible. Recurrence is common in cases of incomplete resection. Gamma knife radiosurgery was used to treat two patients with primary tumors of the endolymphatic sac and one recurrent case. All three patients were alive at 75, 74, and 11 months, respectively, after gamma-knife treatment, and the tumors were either smaller or had not enlarged. None of the patients experienced radiation-related side effects during follow up. Gamma knife radiosurgery should be considered a treatment option for these surgically challenging tumors.

**KEYWORDS:** Endolymphatic sac tumor, Gamma knife, Radiosurgery

## INTRODUCTION

Tumors of the endolymphatic sac (ESTs) are rare adenocarcinomas of the temporal bone. These neoplasms are slow-growing but highly invasive, and wide excision is crucial for successful treatment. However, given their anatomic location and invasive nature, total resection of ESTs tends to be difficult and recurrence is common (7). Gamma-knife radiosurgery (GKR) is another treatment option for ESTs that are unresectable, only partially resectable, or recurrent. The literature describes relatively few cases of ESTs treated with GKR (1,4,5,8). Here we report three cases of EST, two primary tumors and one recurrent mass that were treated successfully with GKR.

## CASE REPORTS

### Patient 1

A 58-year-old man presented in January 2008 with headache and dizziness. His history included 1.5 years of left-sided

progressive hearing loss and tinnitus, as well as vertigo. He had also experienced sudden bleeding from his left ear 10 days prior to presentation. Magnetic resonance imaging (MRI) showed a lobular tumor in the patient's left temporal bone. The mass was hyperintense on T2-weighted images and enhanced heterogeneously with contrast (Figure 1A, B). The tumor volume was 2.5 cm<sup>3</sup>. Gamma-knife radiosurgery was performed with a prescribed dose of 18 Gy administered to the 50% isodose line. At 75 months after GKR, follow-up MRI showed reduced tumor size. The patient had no additional cranial nerve deficits and his vertigo had partially resolved. There were no side effects of radiation.

### Patient 2

A 26-year-old woman presented in February 2008 complaining of headache. Sixteen months earlier, she had had a tumor in her left pontocerebellar angle surgically resected. Histopathological examination had identified the mass as an EST. Physical examination revealed left facial nerve paralysis, left-sided sensorineural hearing loss, and vertigo. MRI demon-



Corresponding author: Selçuk PEKER

E-mail: peker@selcukpeker.com

strated a recurrent tumor that was lobulated and enhanced heterogeneously with contrast on T1-weighted images, and that was hyperintense on T2-weighted images (Figure 2A, B). The volume of the tumor was 4.7 cm<sup>3</sup>. The patient underwent GKR with a prescribed dose of 17 Gy administered to the 50% isodose line. After 74 months of follow-up, MRI revealed that the EST was almost totally gone. The patient's headache issues had partially resolved.

**Patient 3**

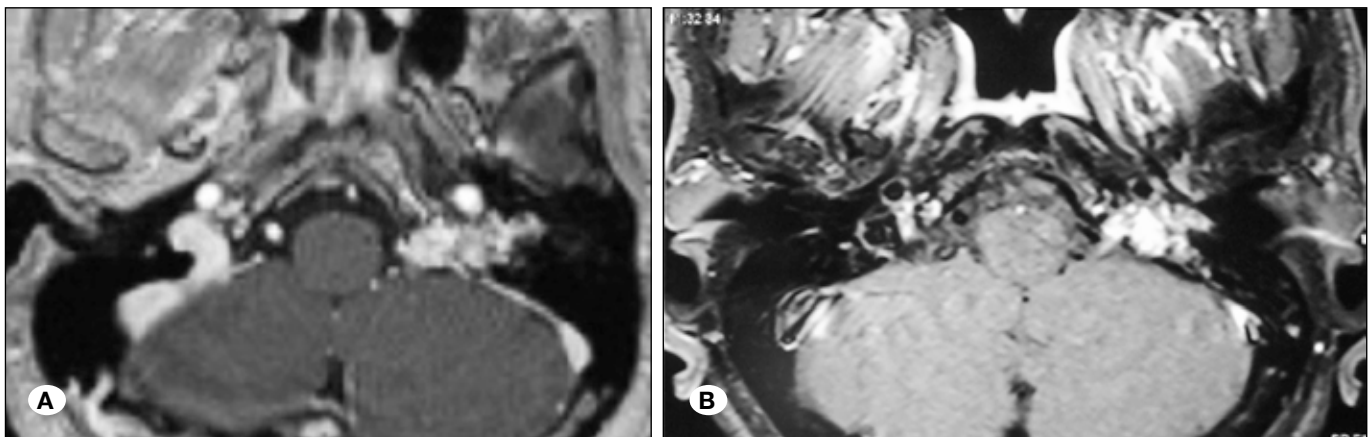
A 62-year-old woman presented in January 2012 with sudden left-sided hearing loss, headache, vertigo, and tinnitus. She had had these symptoms for 1 month. MRI showed a tumor in the petrous portion of the patient's left temporal bone. The mass was exterior to the internal acoustic canal and could not be differentiated from cranial nerves VII and VIII. It was hyperintense on T2-weighted images and enhanced heterogeneously with gadolinium injection (Figure 3A, B). The tumor volume was 1.9 cm<sup>3</sup>. In May 2012, GKR was performed with a prescribed dose of 15 Gy administered to the 50% isodose line. Eleven months later, follow-up MRI showed that

the tumor had not enlarged. There were no changes in the patient's clinical signs. She experienced no radiation-related side effects.

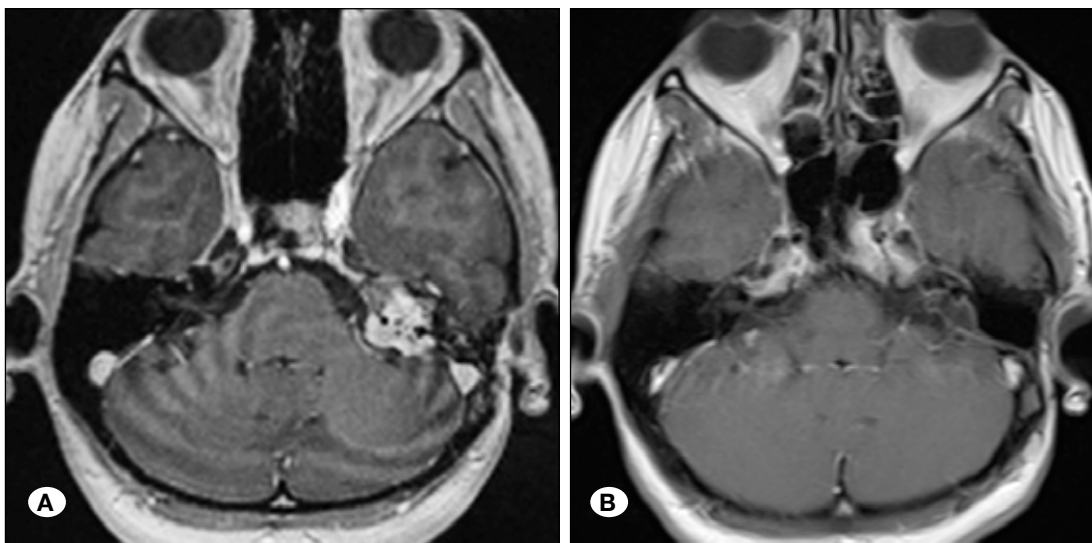
**DISCUSSION**

Hassard and Boudreau described the first EST in 1984 (9). In 1989, a histopathological study by Heffner identified these lesions as low-grade tumors that likely arise from the epithelial lining of the endolymphatic system (10). Despite their benign histopathological appearance, ESTs are locally destructive. Involvement of the petrous apex with extension to the cerebellopontine angle and posterior cranial fossa is common (16). As well, there have been reports of ESTs metastasizing to the brainstem and spinal cord (3-5,17). These tumors are common hereditary manifestations of Von Hippel Lindau disease and may also occur sporadically, as in our three cases (13).

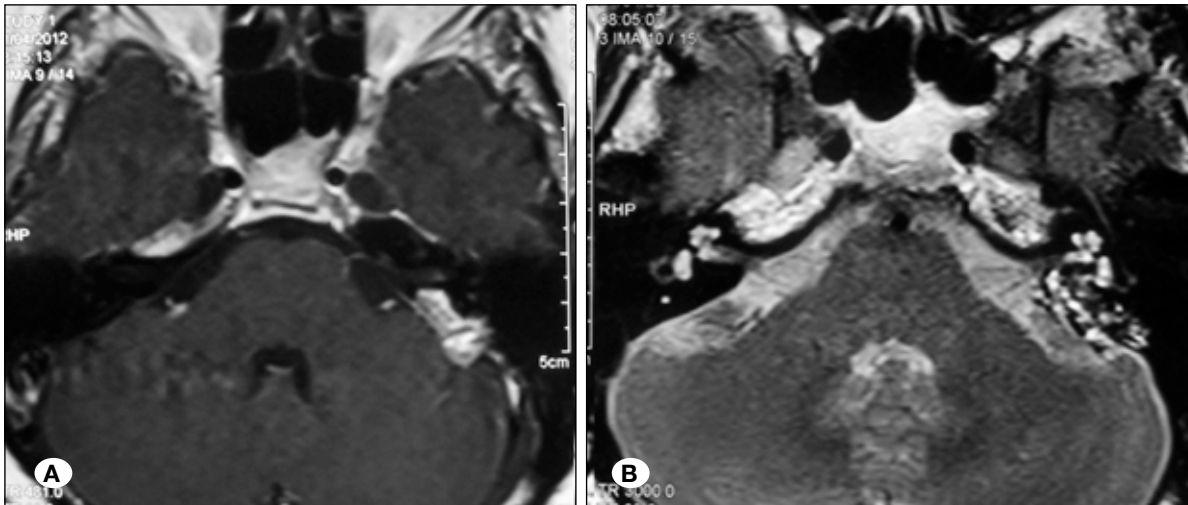
The most consistent early symptom of EST is progressive sensorineural hearing loss, and this may be accompanied



**Figure 1:** T1-weighted contrast enhanced axial MR images of the tumor pre-gamma knife (A) and 75-months after gamma knife (B) demonstrating the regression of the tumor.



**Figure 2:** T1-weighted contrast enhanced axial MR images of the tumor pre-gamma knife (A) and 74-months after gamma knife (B) demonstrating almost totally disappearance of the tumor.



**Figure 3:** T1-weighted contrast enhanced (A) and T2-weighted (B) axial MR images of the tumor.

by tinnitus, vertigo, headache, disequilibrium, facial nerve paralysis, or other palsies caused by involvement of nearby cranial nerves. However, diagnosing this neoplasm is clinically and radiologically challenging. Tumors of the endolymphatic sac can be easily confused with other masses that arise in the cerebellopontine angle, such as paragangliomas, choroid plexus papillomas, papillary meningiomas, vestibular schwannomas and metastases (16).

Patel et al. and Mukherji et al. reported specific imaging findings for ESTs (14,15) Radiologically, these lesions can be identified along the margin of the posterior petrosal plate between the sigmoid sinus and the internal auditory canal. Computed tomography often shows bone destruction in the petrous portion of the temporal bone. On MRI, T1-weighted images may reveal calcifications as well as hyperintense, hemorrhagic, or proteinaceous cystic components. The combined findings of hyperintense focal signals on T1-weighted images without contrast injection, heterogeneous enhancement on T1-weighted images with gadolinium injection, and heterogeneous signal on T2-weighted images help to differentiate ESTs from other tumors of the cerebellopontine angle (14). Baltacıoğlu et al. presented 2 cases of ESTs that exhibited a hypointense central region and a hyperintense rim on T1-weighted images, and heterogeneous enhancement with contrast on T1-weighted images (2). On angiography, ESTs often appear as hypervascular masses with intracranial or extracranial blood supply (2). Unlike paragangliomas, which have capsule that is distinct on angiography, the borders of ESTs appear irregular and ill-defined on angiographic images. One report on angiographic findings for 20 ESTs noted that the center of these tumors exhibit marked contrast enhancement, and that this fades towards the periphery (14).

The treatment of choice for EST is complete surgical excision, and the surgical approach is selected based on the size of the tumor and its anatomic relationship to critical structures (12). Incomplete resection of ESTs is common and there is an unusually high rate of local recurrence after surgery. This has been attributed to the aggressive biological behavior of these tumors, and to intraoperative bleeding issues due to their hypervascularity (11).

The role of radiotherapy, including GKR, in the treatment of ESTs is controversial. The current literature contains 4 small reported series in which GKR was applied after recurrence (Table I). Ferreira et al. reported 2 such cases in 2002 (5). One patient was an 11-year-old girl who underwent total resection of an EST initially, followed by subtotal resection of a recurrent mass 4.5 years later. The residual tumor was immediately treated with GKR, and examination after 2 years of follow-up revealed no enlargement of the lesion. The authors' second case was a 43-year-old man whose EST was treated with surgery (gross total resection) and conformal radiotherapy postoperatively. Four years later, examination revealed tumor recurrence and a single remote cerebellar metastasis. These lesions were treated with GKR. Two years later, some of the nodules had increased in size and these were addressed with repeat GKR. At 7 years after surgery, neither patient was disease-free but both were neurologically stable.

Hashimoto et al. described a single case of recurrent EST associated with Von Hippel Lindau disease in a 44 year-old man (8). Immediately after the second surgery, the patient underwent LINAC stereotactic radiosurgery (STR) with a marginal dose of 24 Gy. Four years after STR, the tumor was found to have enlarged, and GKR was performed with a marginal dose of 26 Gy. A fourth operation was carried out 32 months after GKR, and histopathological examination revealed tumor cell depletion, fibrosis, and hyalinized and thickened walls of the vessels in the specimen. Prior to STR, a biopsy had revealed proliferation of glandular tumor cells and a highly vascular mass.

Cheng et al. described the case of a 44-year-old man who underwent surgical treatment for 3 ESTs, one in each cerebellopontine angle and one in the vermis of the cerebellum (4). Upon detection of the 3 lesions, only the mass in the left cerebellopontine angle was removed. Pathological examination identified this lesion as an EST. As the patient refused surgery for the lesion in the right cerebellopontine angle, GKR was performed with a prescribed dose of 17 Gy to the 50% isodose line. In the 27 months that followed the initial GKR, the patient underwent 3 additional GKR sessions to treat recurrent tumors. Six months after the final GKR session, the patient was stable and imaging revealed no tumor expansion.

**Table 1:** Summary of Patient and Tumor Characteristics, Treatments and Outcomes for all Cases to Date in Which Endolymphatic Sac Tumors have been Treated with Gamma-Knife Radiosurgery

Authors (year)	Age(years)/ Sex	Size	Treatment Pre-GKR	Dose (Gy)	Complications	Follow-up after GKR
Ferreira et al. (2002)						
Case 1	11/F	NR	Operated twice	NR	Seizures	3 years with no tumor enlargement
Case 2	43/M	NR	Gross-total surgical resection and conformal RT	NR	NR	After 4 years, new metastatic lesions remote from treated site; these were treated with GKR also and were reported as stable with no new lesions
Hashimoto et al (2004)						
	44/M	NR	Surgery and STR	26	NR	Two more surgeries after GKR due to tumor enlargement
Balasubramaniam et al. (2009)						
	41/M	7.4 cm <sup>3</sup>	Gross-total surgical resection	15	No side effects	At 2.5 years post-GKR, tumor size was reduced; at 3 years post-GKR, patient was clinically asymptomatic with no neurologic deficits
Cheng et al. (2011)						
	44/M	0.6x0.2x0.1 cm	Surgery only for lesion in left CPA	17 to right-side lesion 11 and 16 for other tumors	NR	Tumor in right CPA regressed initially after GKR; recheck at 27 months post-GKR showed recurrence, which was treated with second round of GKR; patient was reported disease-free 6 months later
Our study						
Case 1	58/M	2.5 cm <sup>3</sup>	-	18	No side effects	In 75 months of follow-up, tumor size decreased
Case 2	26/F	4.7 cm <sup>3</sup>	Gross-total surgical	17	No side effects	In 74 months of follow-up, tumor size decreased
Case 3	62/F	1.9 cm <sup>3</sup>	-	15	No side effects	In 11 months of follow-up, tumor is stable

**CPA:** Cerebellopontine angle, **GKR:** Gamma-knife radiosurgery, **STR:** Stereotactic radiotherapy, **RT:** Radiotherapy, **NR:** Not reported.

Balasubramaniam et al. reported a 44-year-old man who had a mass in his right jugular fossa that was resected and diagnosed as EST upon histopathological examination (1). Two years later, tumor recurrence was detected and GKR was performed with 15 Gy administered to the 50% isodose line. At 2.5 years after GKR, MRI showed reduced tumor size. The patient was clinically asymptomatic at his 3-year follow-up exam.

Table I summarizes the case management and treatment outcomes for each of these above-noted series. In addition to these reports, the literature documents several EST cases that have been managed with postoperative conformal radiotherapy, intensity-modulated radiotherapy, stereotactic radiotherapy, and one case of primary treatment with radiotherapy, which was the approach used in 2 of our 3 cases (6,11,18). Kamida et al. described a case of EST in which the primary treatment was conventional radiotherapy and chemotherapy, and this patient's recurrent tumor was successfully treated with SRT (11). A marginal dose of 21 Gy was administered to this lesion, and an MRI scan 2 year later revealed that the mass had regressed. All of these additional reports document positive response to radiotherapy, which suggests that this is an effective treatment for ESTs.

According to the EST cases that have been documented to date, 15-18 Gy is an effective dose range for GKR and these doses have minimal adverse effects. Our limited experience with GKR as treatment for EST confirms that, with proper dose planning, GKR is effective for treating these tumors. Further, the cases to date suggest that GKR is generally associated with less morbidity than surgery in this patient group. There is a need to evaluate GKR in a larger number of EST cases in order to determine the optimal role for this treatment method in this patient group. Based on current knowledge, it is reasonable to administer GKR as a primary therapy for EST, after subtotal resection, or after surgery in cases of recurrence.

## ■ REFERENCES

- Balasubramaniam S, Deshpande RB, Misra BK: Gamma knife radiosurgery in jugular foramen endolymphatic sac adenocarcinoma. *J Clin Neurosci* 16:710-711, 2009
- Baltacıoğlu F, Ekinci G, Türe U, Sav A, Pamir N, Erzen C: MR imaging, CT, and angiography features of endolymphatic sac tumors: Report of two cases. *Neuroradiology* 44:91-96, 2002
- Bambakidis NC, Rodrigue T, Megerian CA, Ratcheson RA: Endolymphatic sac tumor metastatic to the spine: Case report. *J Neurosurg Spine* 3:68-70, 2005
- Cheng X, Qin S, Wang X, Li P, Shrestha B, Wang W: Gamma knife treatment of an endolymphatic sac tumor: Unique features of a case and review of the literature. *Neurol India* 59:608-611, 2011
- Ferreira MA, Feiz-Erfan I, Zabramski JM, Spetzler RF, Coons SW, Preul MC: Endolymphatic sac tumor: Unique features of two cases and review of the literature. *Acta Neurochir (Wien)* 144:1047-1053, 2002
- Gupta R, Vaidhyswaran AN, Murali V, Kameswaran M: Endolymphatic sac papillary carcinoma treated with surgery and post-operative intensity-modulated radiotherapy: A rare case report. *J Cancer Res Ther* 6:540-542, 2010
- Hansen MR, Luxford WM: Surgical outcomes in patients with endolymphatic sac tumors. *Laryngoscope* 114:1470-1474, 2004
- Hashimoto M, Yokota A, Urasaki E, Imada H, Yamamoto H: Surgical treatment of endolymphatic sac tumor with adjunctive stereotactic radiation therapy-case report. *Neurol Med Chir (Tokyo)* 44:595-599, 2004
- Hassard AD, Boudreau SF, Cron CC: Adenoma of the endolymphatic sac. *J Otolaryngol* 13:213-216, 1984
- Heffner DK: Low-grade adenocarcinoma of probable endolymphatic sac origin. A clinicopathologic study of 20 cases. *Cancer* 64 :2292-2302, 1989
- Kamida T, Isono M, Inoue R, Wakabayashi Y, Goda M, Ishii K, Kobayashi H: Stereotactic radiosurgery for aggressive papillary tumor of the temporal bone: Case report. *Surg Neurol* 58:124-1277, 2002
- Kim HJ, Hagan M, Butman JA, Baggenstos M, Brewer C, Zalewski C, Linehan WM, Lonser RR: Surgical resection of endolymphatic sac tumors in von Hippel-Lindau disease: Findings, results, and indications. *Laryngoscope* 123:477-483, 2013
- Lonser RR, Kim HJ, Butman JA, Vortmeyer AO, Choo DI, Oldfield EH: Tumors of the endolymphatic sac in von Hippel-Lindau disease. *N Engl J Med* 350:2481-2486, 2004
- Mukherji SK, Albernaz VS, Lo WW, Gaffey MJ, Megerian CA, Feghali JG, Brook A, Lewin JS, Lanzieri CF, Talbot JM, Meyer JR, Carmody RF, Weissman JL, Smirniotopoulos JG, Rao VM, Jinkins JR, Castillo M: Papillary endolymphatic sac tumors: CT, MR imaging, and angiographic findings in 20 patients. *Radiology* 202:801-808, 1997
- Patel PC, Pellitteri PK, Reams CL, Martin JS, Szymanski MB: Aggressive papillary tumor of the temporal bone: Delayed extensive recurrence following radiation therapy. *Skull Base Surg* 7:45-48, 1997
- Sun YH, Wen W, Wu JH, Song JM, Guan H, Wang KX, Xu MQ: Endolymphatic sac tumor: Case report and review of the literature. *Diagn Pathol* 2:7-36, 2012
- Tay KY, Yu E, Kassel E: Spinal metastasis from endolymphatic sac tumor. *AJNR Am J Neuroradiol* 28:613-614, 2007
- Yu SJ, Chen YD, Gao F, Qiu XG, Chang H: Endolymphatic sac papillary tumor: A case report. *Chin Med J (Engl)* 124:3828-382, 2011